

Trans radial CTO complicated by Left main dissection

Dr.P.K.Asokan

M.D,D.M, FSCAI, FACC, FESC

Chief Intervention Cardiologist

Fathima Heart Foundation

Calicut, Kerala,

India.

- 44 F
- DM
- HTN
- HL
- NSTE AWMI

- ECHO EF 50%
 RWMA

- TMT 7 METS
 +VE

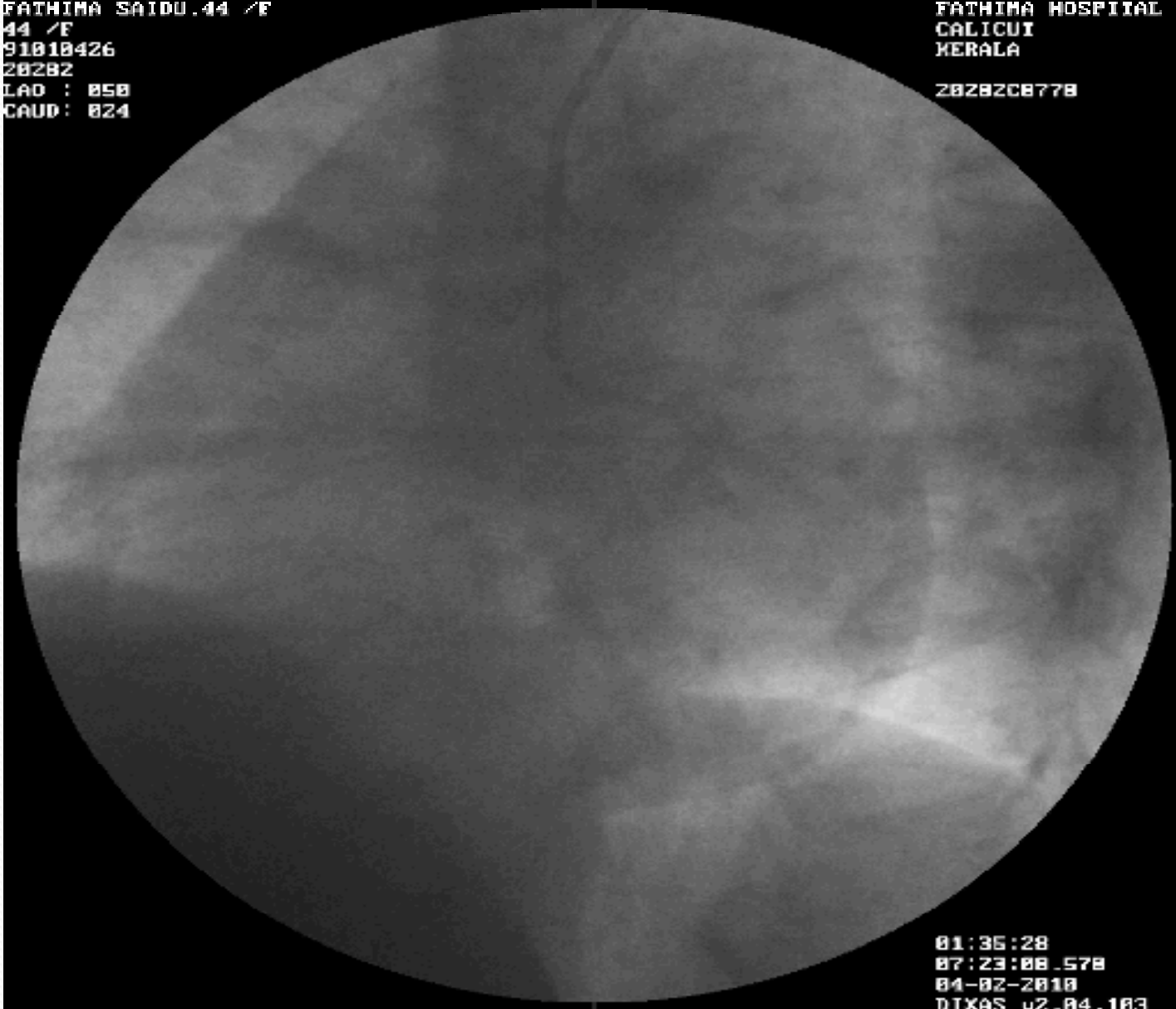
CORONARY ANGIO

- LMCA NORMAL
- LAD MID – TOTAL (CTO)
- LCX (DOMINANT)
 - PROXIMAL 40% STENOSIS
 - DISTAL/LPDA 95% STENOSIS
 - OM₁ SMALL OSTIAL 70%STENOSIS
- * RCA NON DOMINANT

FATHIMA SAIDU.44 /F
44 /F
91818426
28282
LAD : 050
CAUD: 024

FATHIMA HOSPITAL
CALICUT
KERALA

2828ZCB778

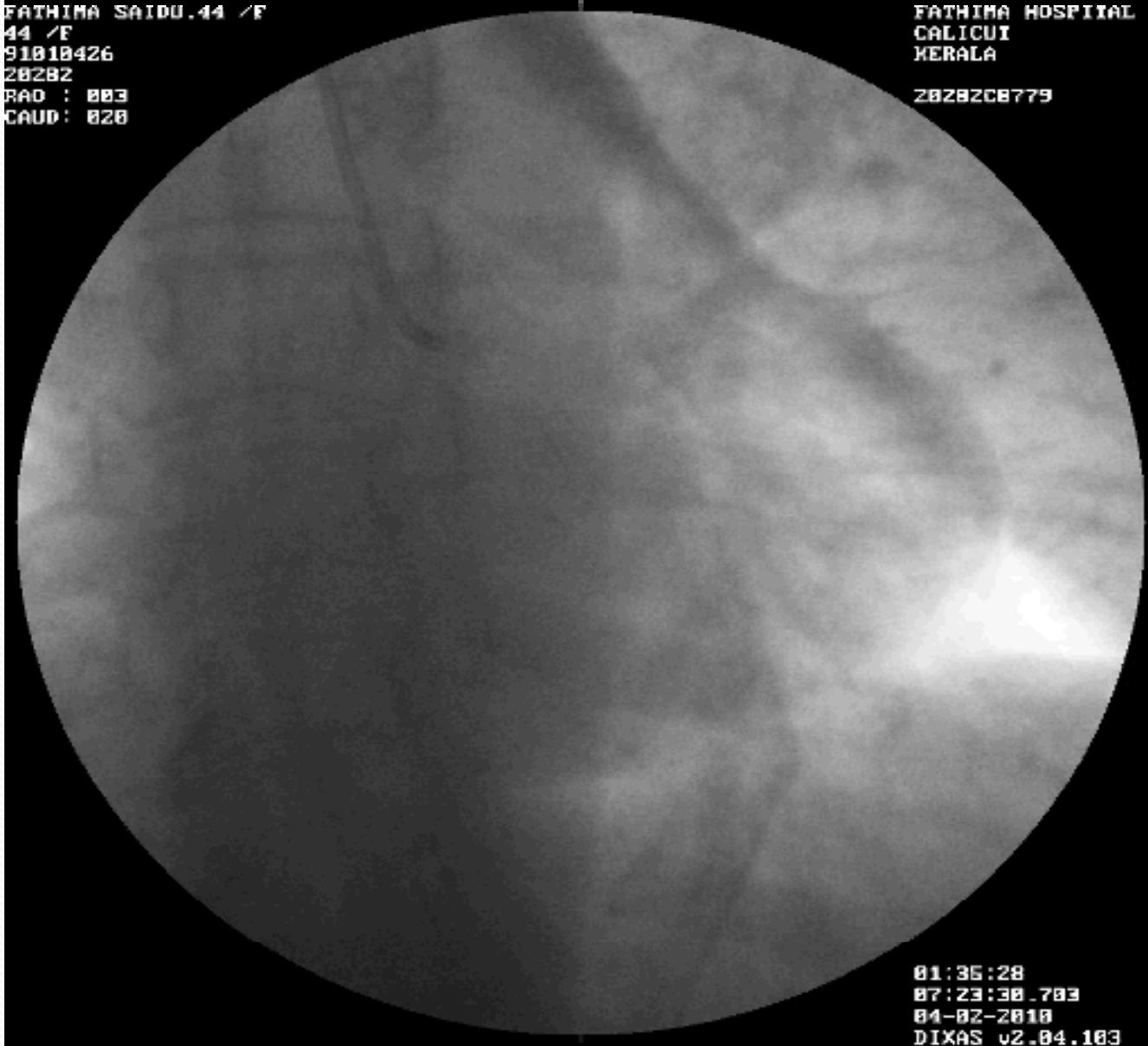


01:36:28
07:23:08.578
04-02-2010
DIXAS v2.04.103

FATHIMA SAIDU.44 /F
44 /F
91010426
20282
RAD : 003
CAUD : 020

FATHIMA HOSPITAL
CALICUI
KERALA

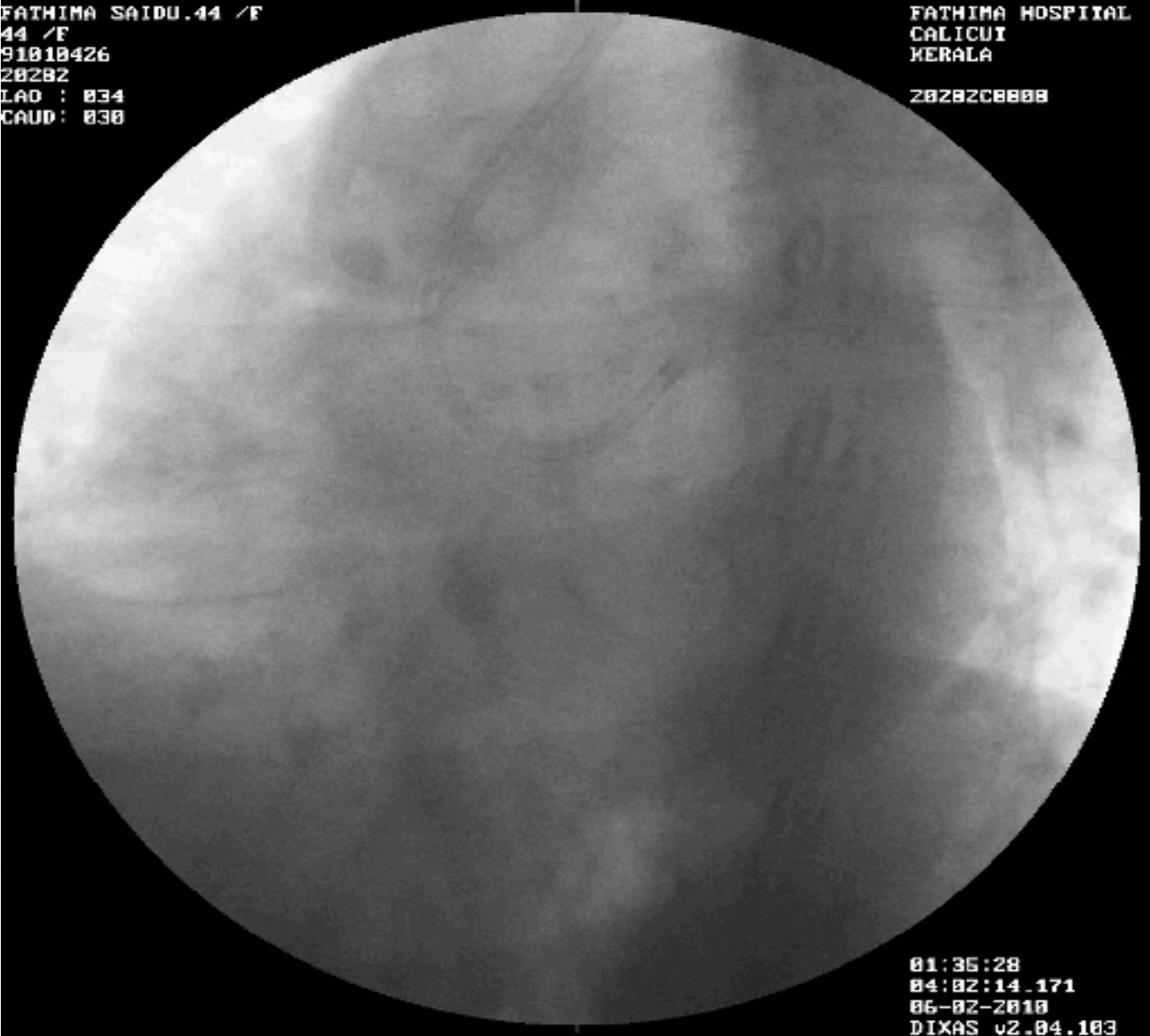
Z0Z0Z0B779



01:36:28
07:23:30.783
04-02-2010
DIXAS v2.04.103

FATHIMA SAIDU.44 /F
44 /F
91010426
20202
LAD : 034
CAUD : 030

FATHIMA HOSPITAL
CALICUI
KERALA
20202C000

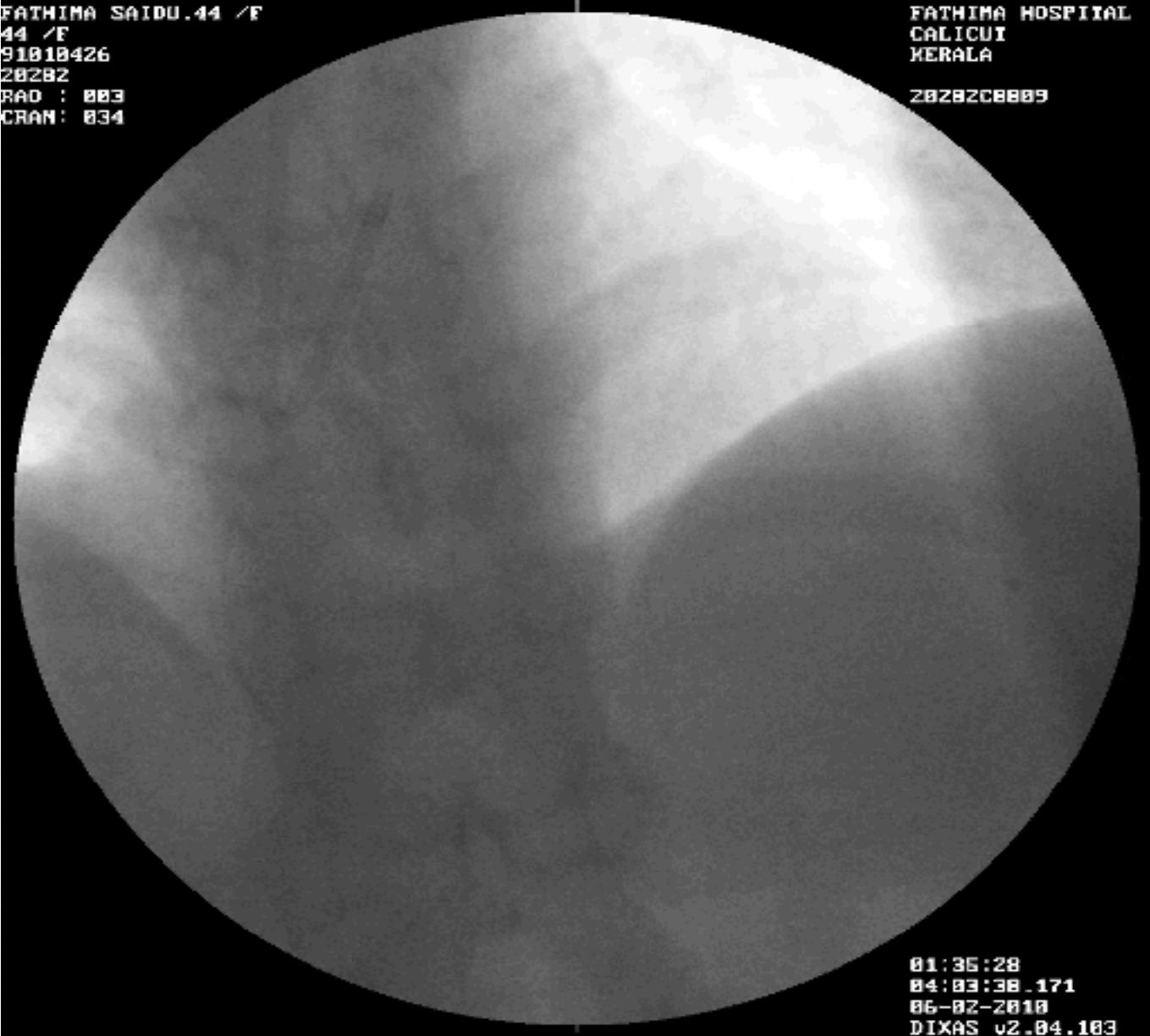


01:35:28
04:02:14.171
06-02-2010
DIXAS v2.04.103

FATHIMA SAIDU.44 /F
44 /F
91010426
20202
RAD : 003
CRAN: 034

FATHIMA HOSPITAL
CALICUI
KERALA

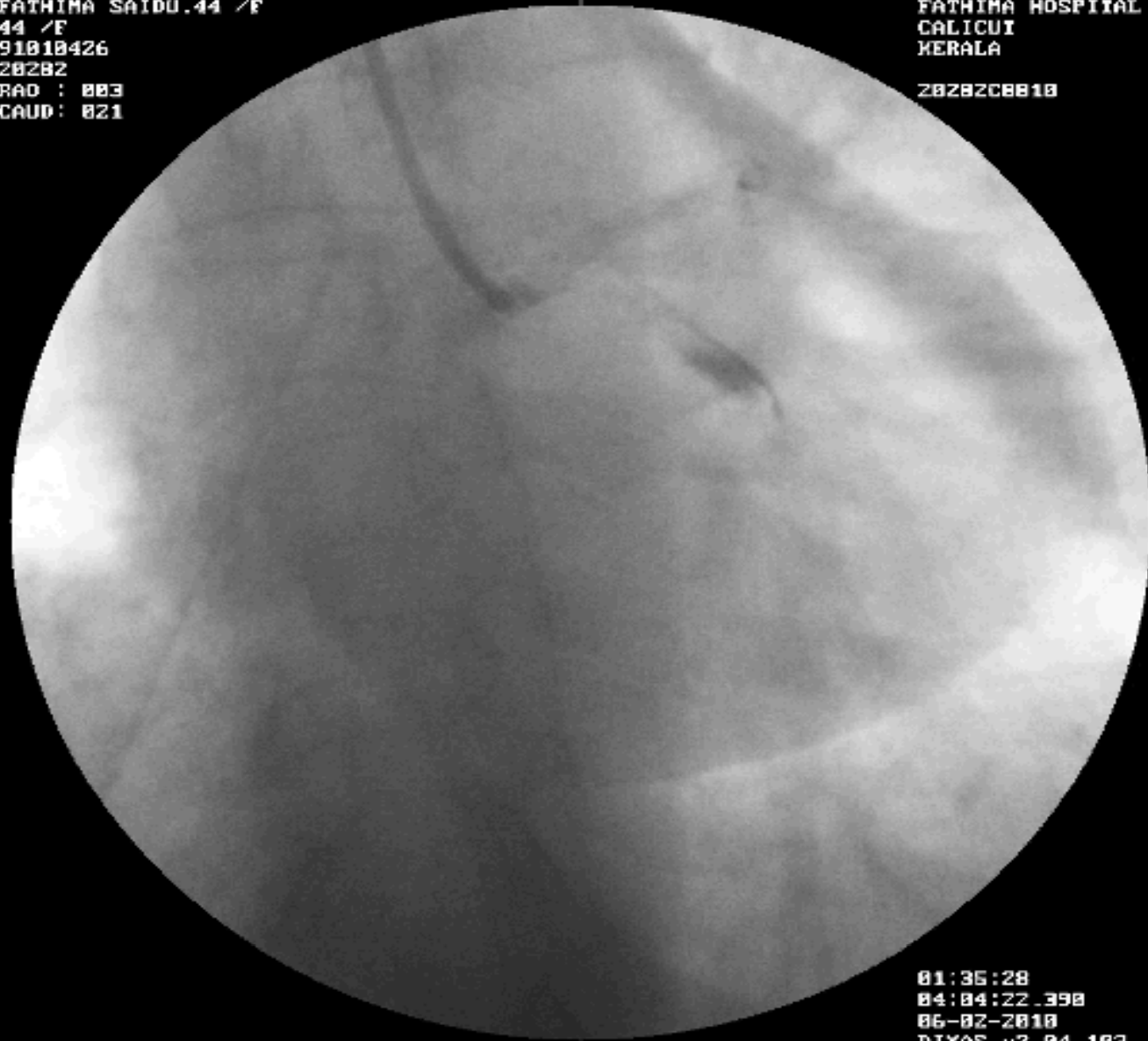20202C0009



01:35:28
04:03:30.171
06-02-2010
DIXAS v2.04.103

FATHIMA SAIDU.44 /F
44 /F
91010426
20202
RAD : 003
CAUD : 021

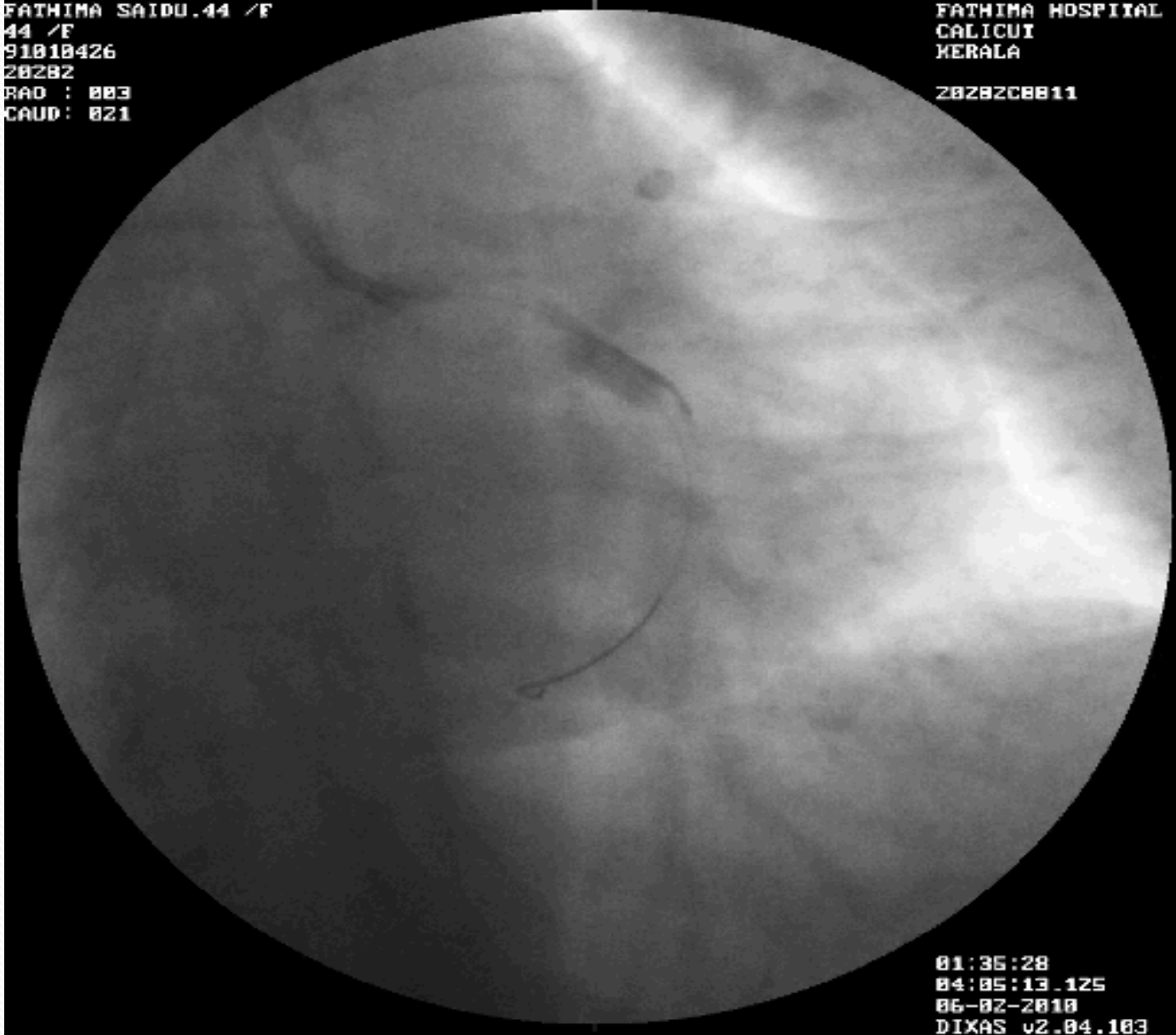FATHIMA HOSPITAL
CALICUT
KERALA
202020010



01:35:28
04:04:22.398
06-02-2010
DIXAS v2.04.103

FATHIMA SAIDU.44 /F
44 /F
91010426
20202
RAD : 003
CAUD : 021

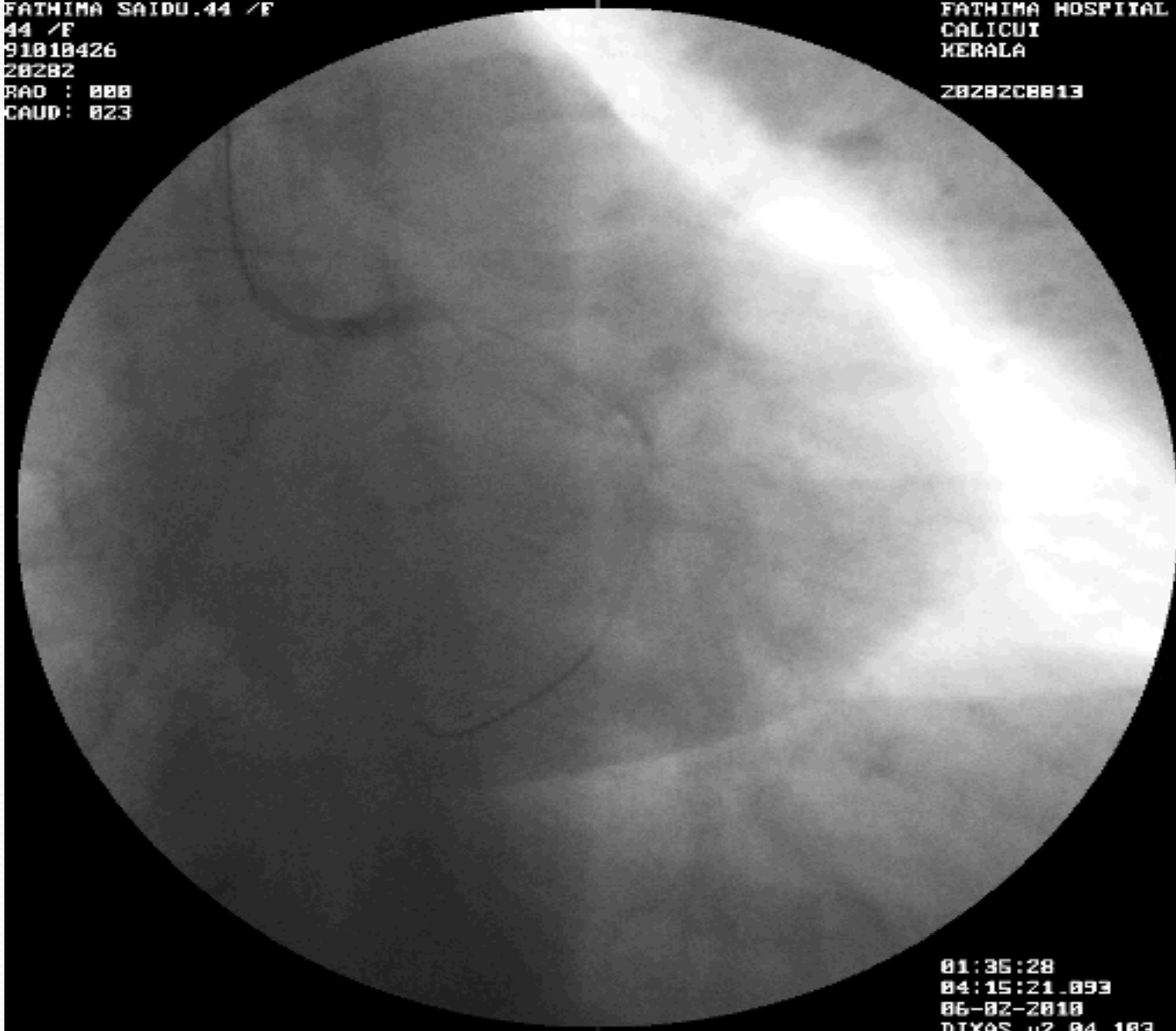
FATHIMA HOSPITAL
CALICUI
KERALA
202020011



01:35:28
04:05:13.125
06-02-2010
DIXAS v2.04.103

FATHIMA SAIDU.44 /F
44 /F
91010426
20202
RAD : 000
CAUD : 023

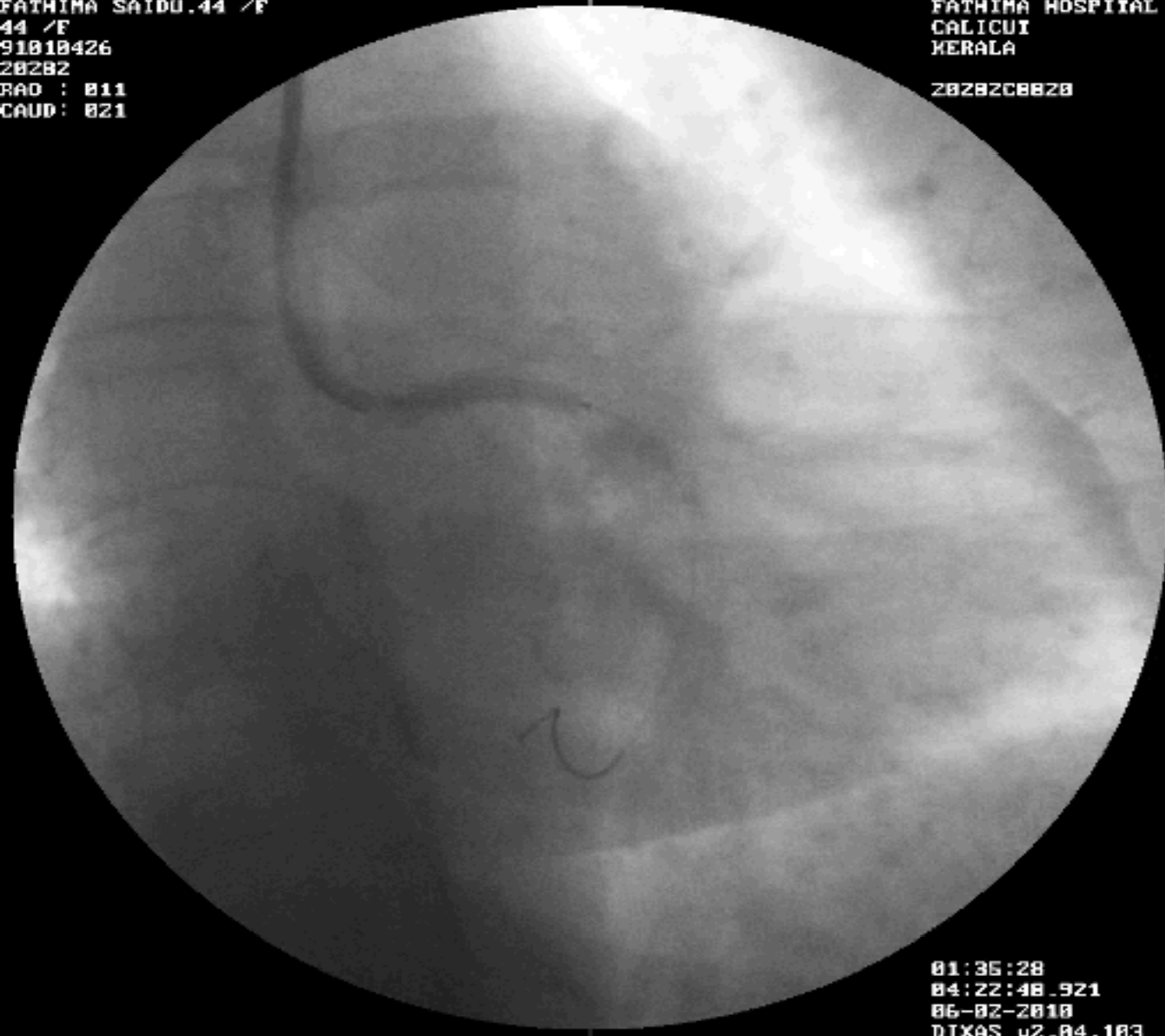
FATHIMA HOSPITAL
CALICUT
KERALA
202020013



01:35:28
04:15:21.093
06-02-2010
DIXAS v2.04.103

FATHIMA SAIDU.44 /F
44 /F
91010426
20202
RAD : 011
CAUD : 021

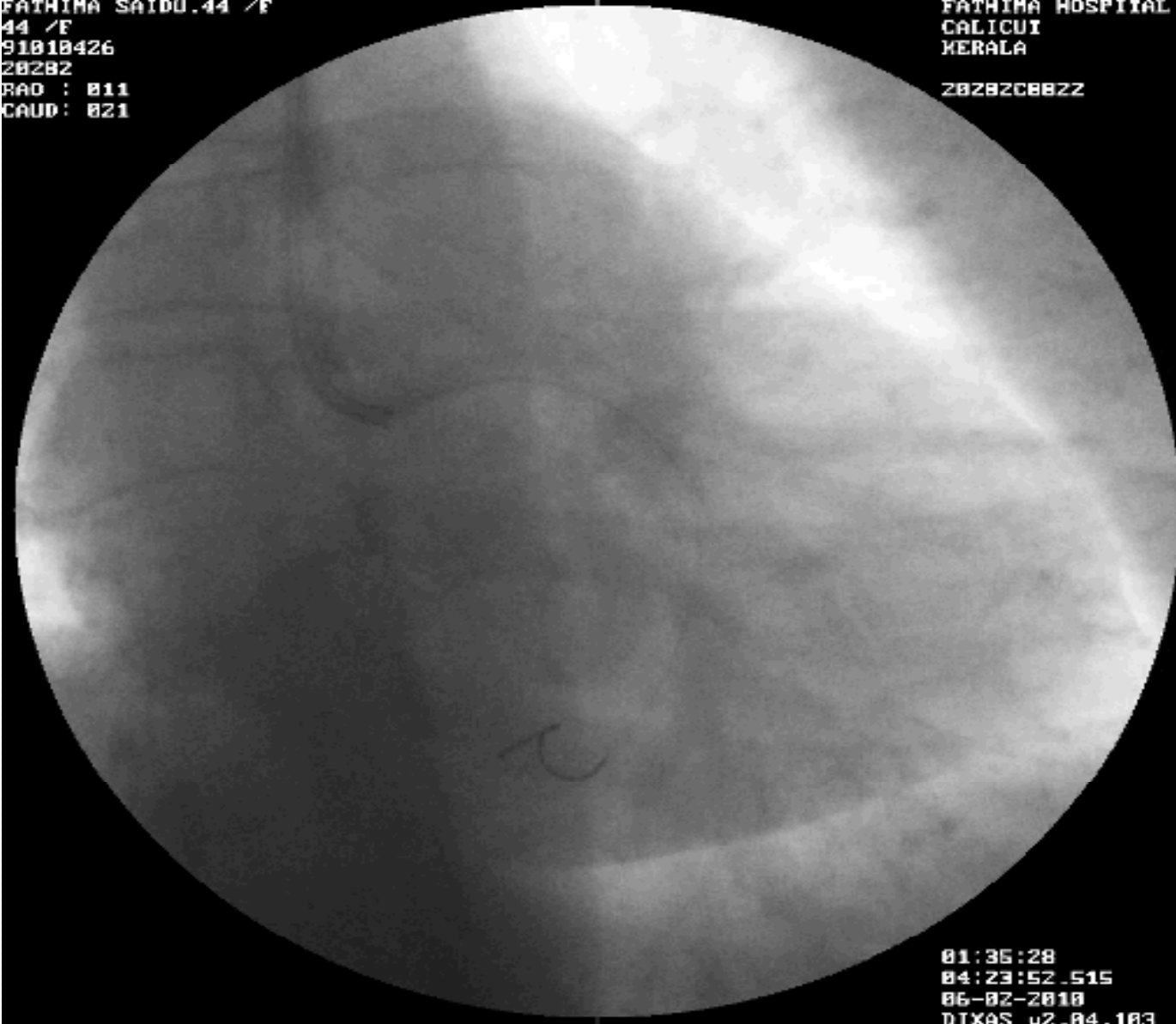FATHIMA HOSPITAL
CALICUI
KERALA
2020200020



01:35:28
04:22:48.921
06-02-2010
DIXAS v2.04.103

FATHIMA SAIDU.44 /F
44 /F
91010426
20202
RAD : 011
CAUD: 021

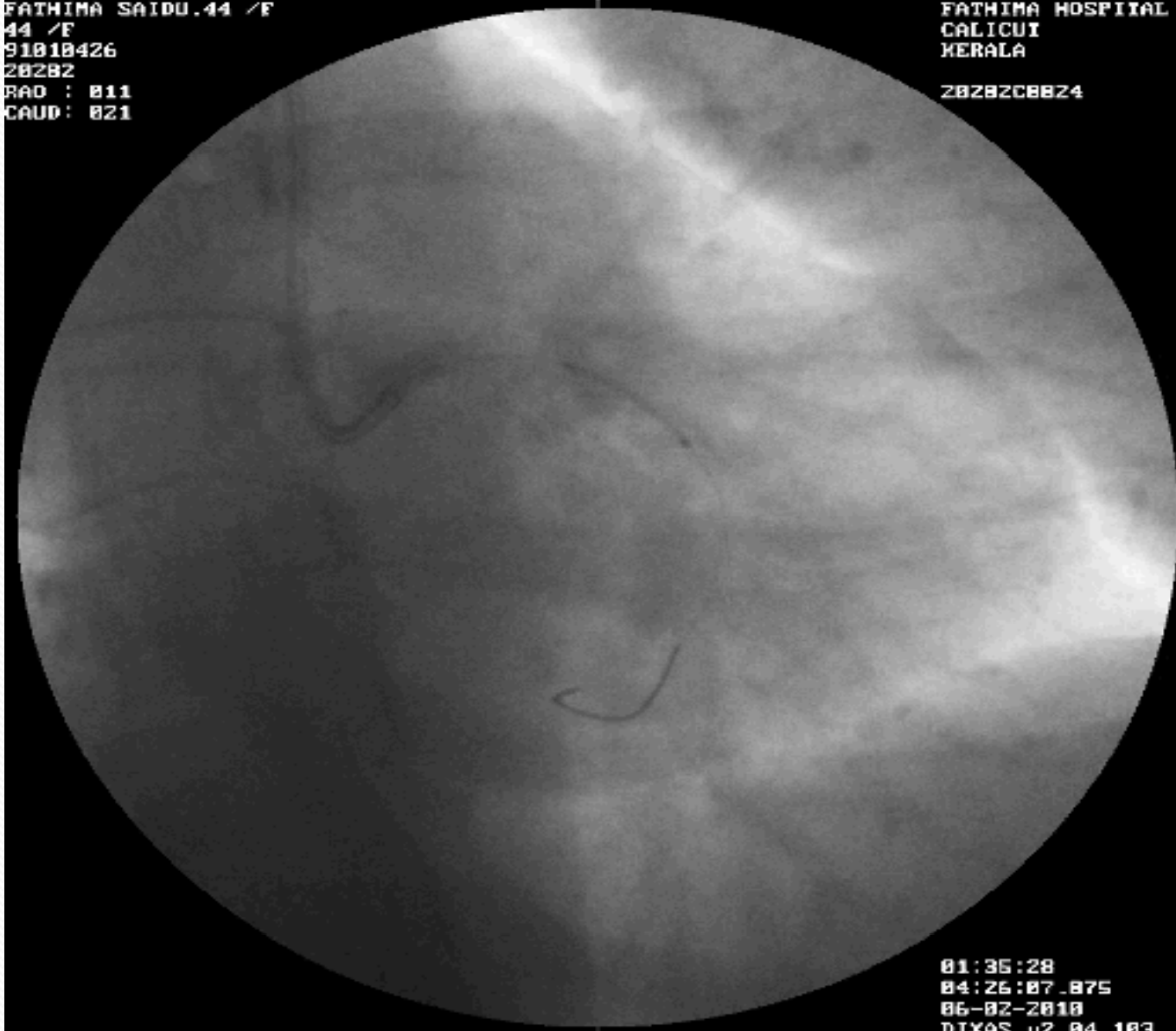
FATHIMA HOSPITAL
CALICUI
KERALA
Z0Z0Z000ZZ



01:35:28
04:23:52.515
06-02-2010
DIXAS v2.04.103

FATHIMA SAIDU.44 /F
44 /F
91010426
20202
RAD : 011
CAUD: 021

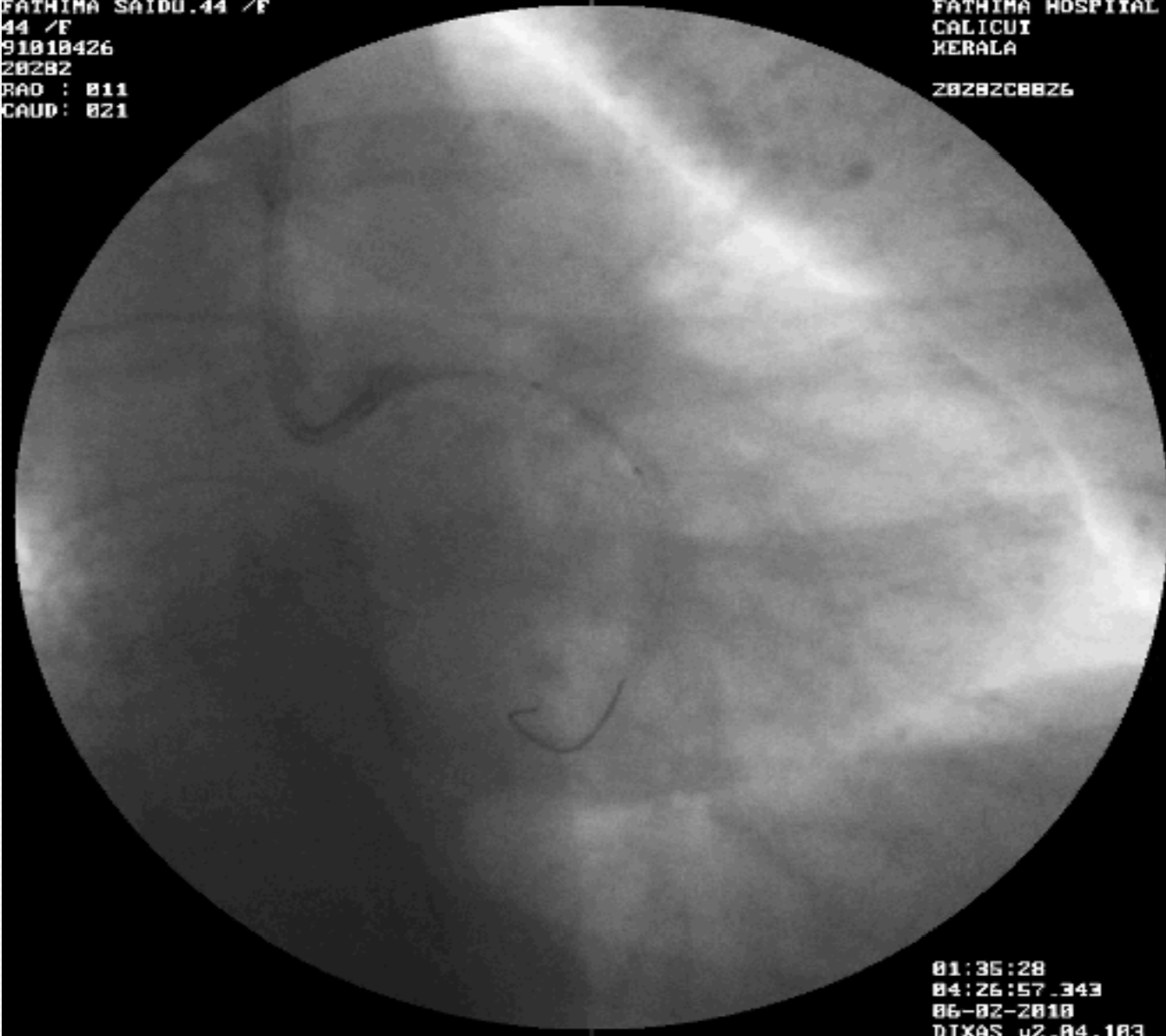
FATHIMA HOSPITAL
CALICUT
KERALA
202020024



01:35:28
04:26:07.075
06-02-2010
DIXAS v2.04.103

FATHIMA SAIDU.44 /F
44 /F
91010426
20202
RAD : 011
CAUD : 021

FATHIMA HOSPITAL
CALICUI
KERALA
202020026

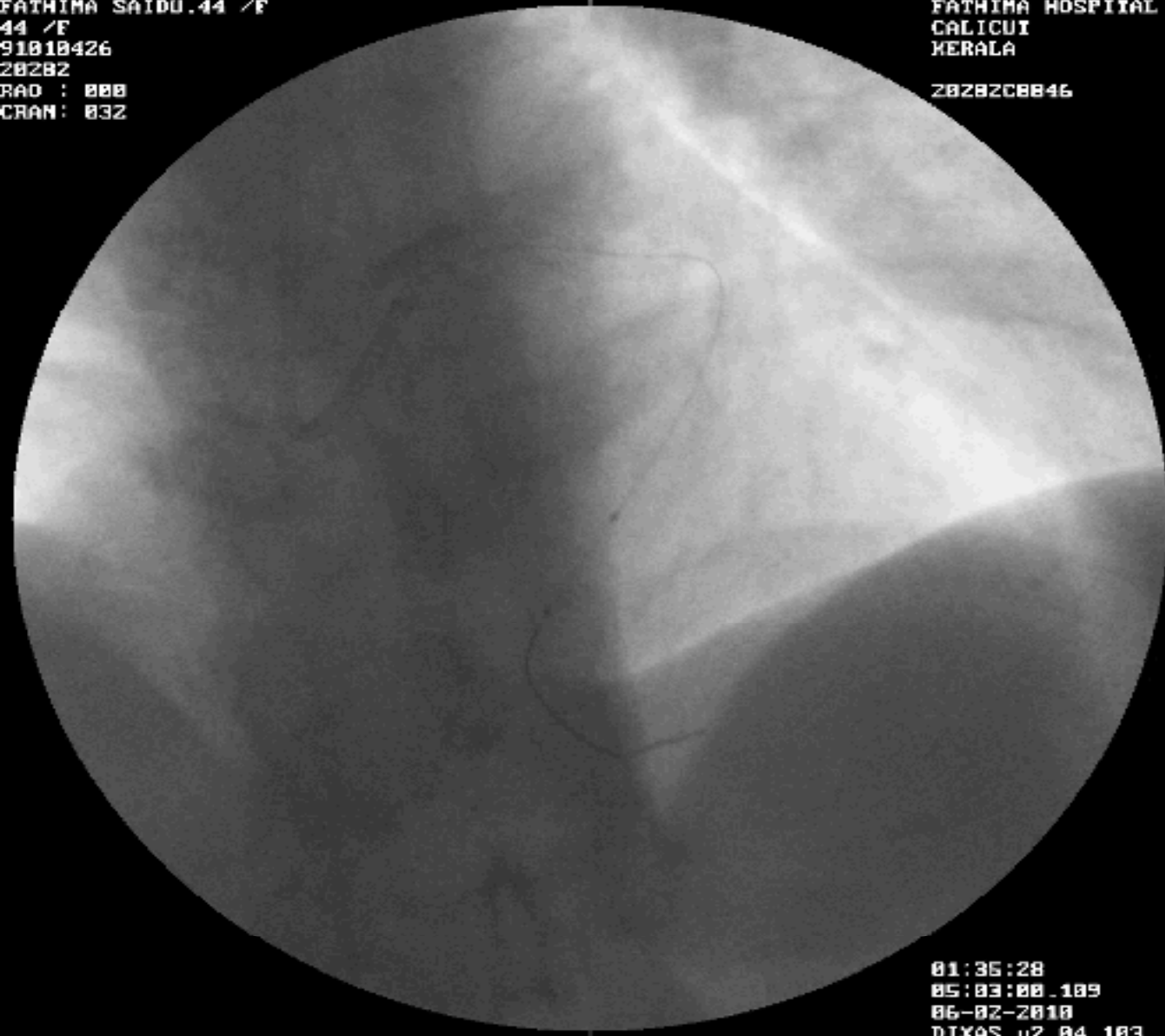


01:35:28
04:25:57.343
06-02-2010
DIXAS v2.04.103

FATHIMA SAIDU.44 /F
44 /F
91010426
20202
RAD : 000
CRAN: 032

FATHIMA HOSPITAL
CALICUI
KERALA

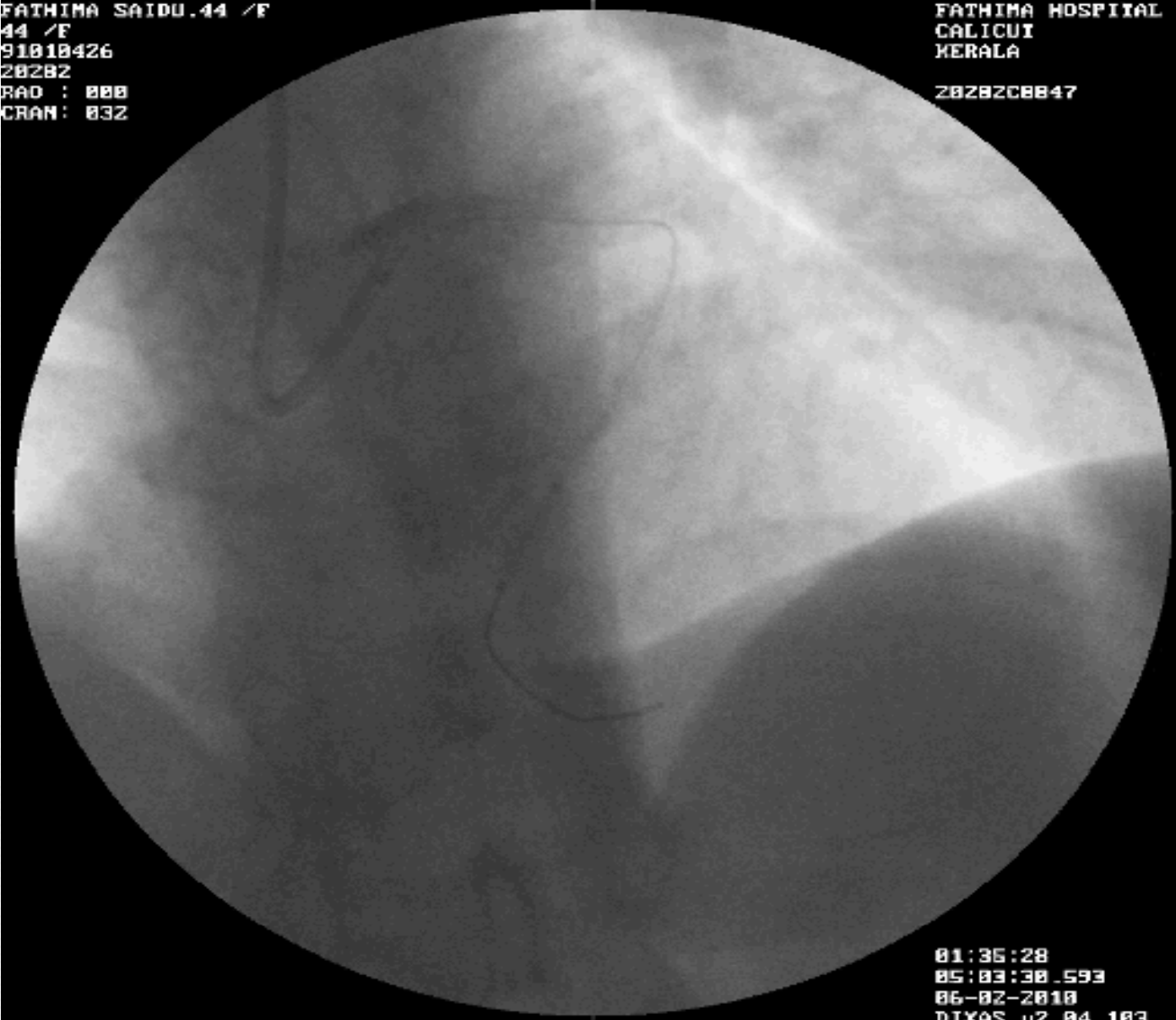20202C0046



01:35:20
05:03:00.109
06-02-2010
DIXAS v2.04.103

FATHIMA SAIDU.44 /F
44 /F
91010426
20202
RAD : 000
CRAN: 032

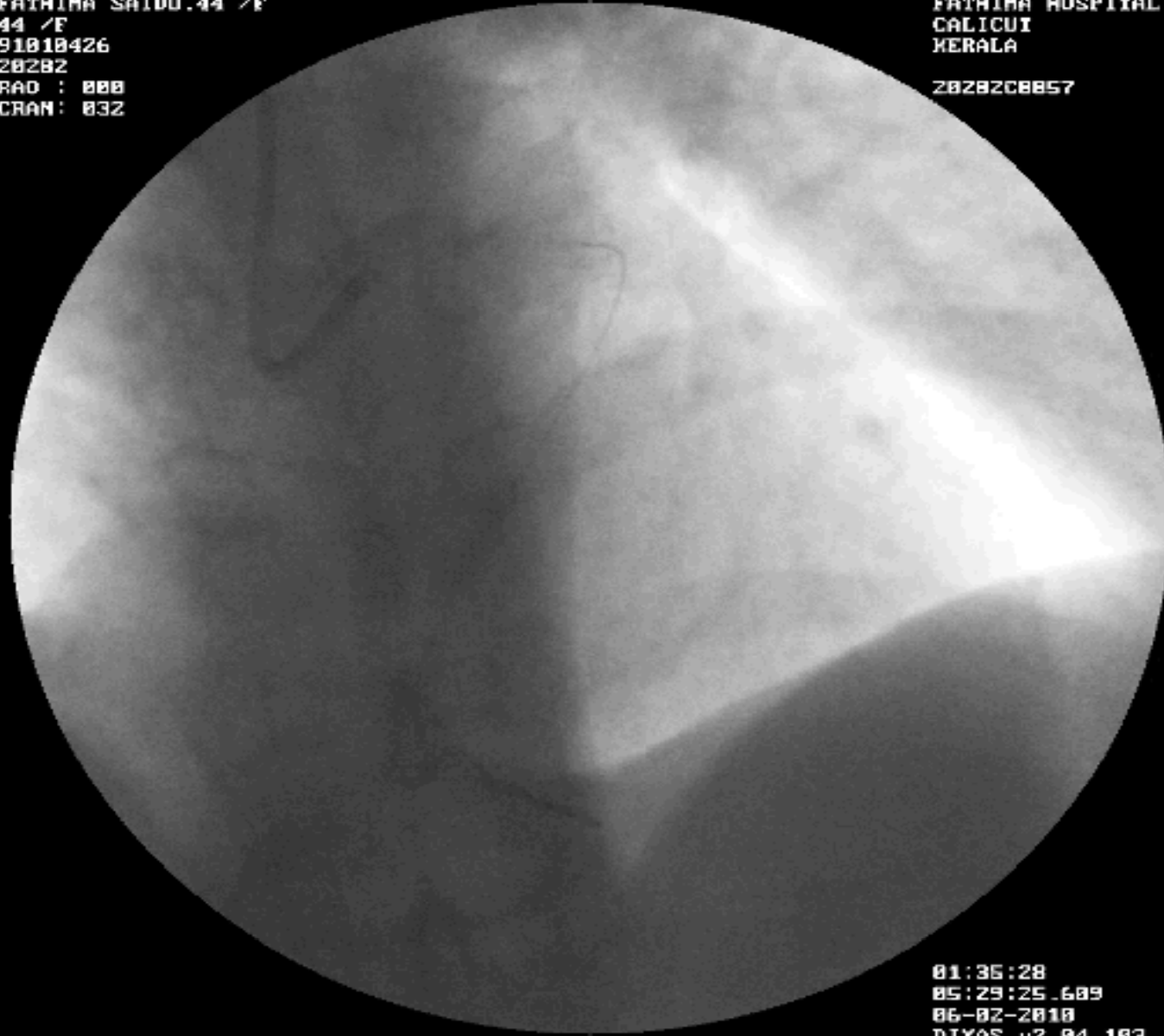
FATHIMA HOSPITAL
CALICUI
KERALA
202020847



01:36:28
05:03:30.593
06-02-2010
DIXAS v2.04.103

FATHIMA SAIDU.44 /F
44 /F
91B1B426
20202
RAD : 000
CRAN: 032

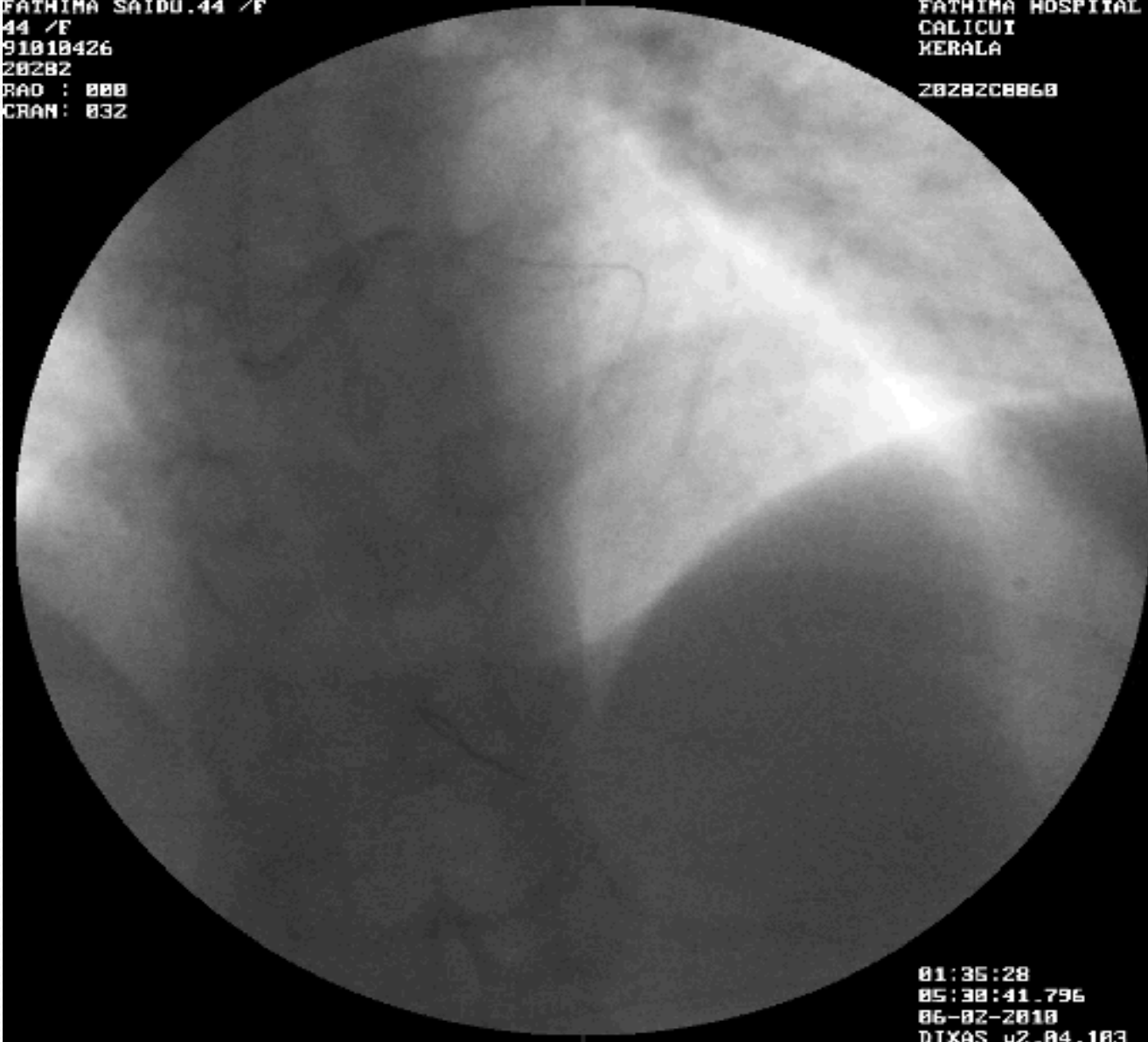
FATHIMA HOSPITAL
CALICUI
KERALA
202020857



01:35:28
05:29:25.689
06-02-2010
DIXAS v2.04.103

FATHIMA SAIDU.44 /F
44 /F
91010426
20202
RAD : 000
CRAN: 032

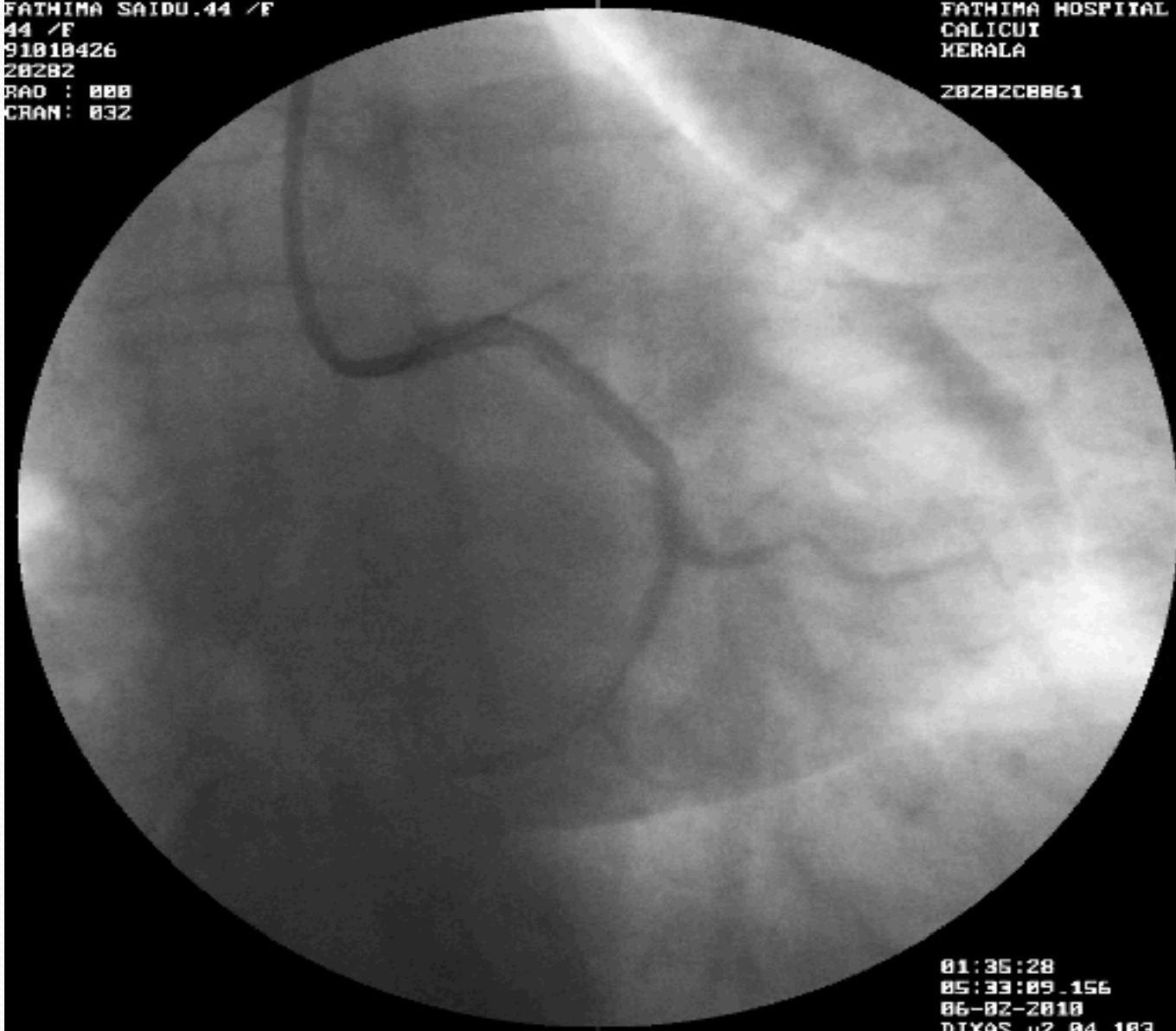
FATHIMA HOSPITAL
CALICUT
KERALA
202020000



01:35:28
05:30:41.796
06-02-2010
DIXAS v2.04.103

FATHIMA SAIDU.44 /F
44 /F
91010426
20202
RAD : 000
CRAN: 032

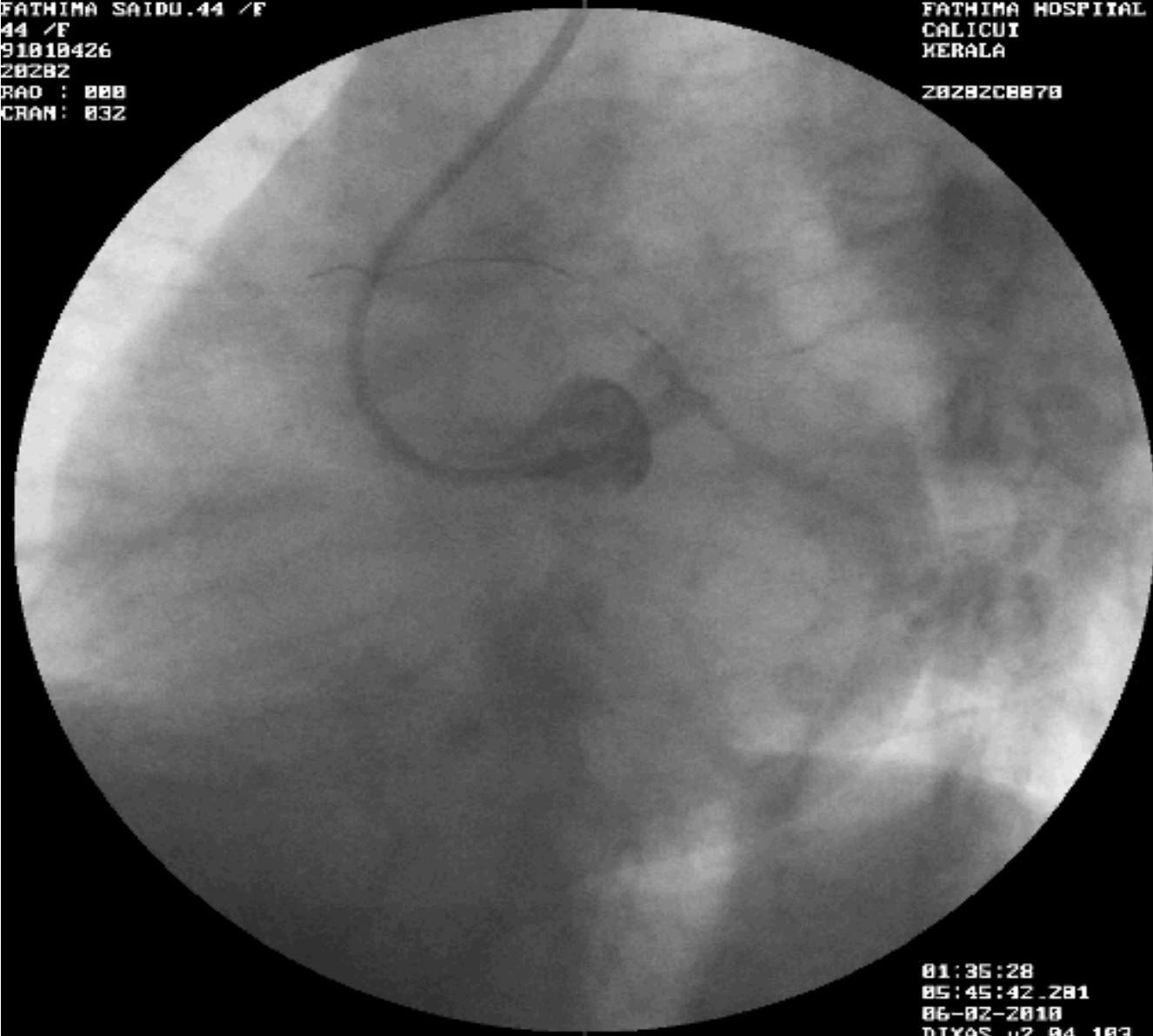
FATHIMA HOSPITAL
CALICUT
KERALA
202020061



01:35:28
05:33:09.156
06-02-2010
DIXAS v2.04.103

FATHIMA SAIDU.44 /F
44 /F
91010426
20202
RAD : 000
CRAN: 032

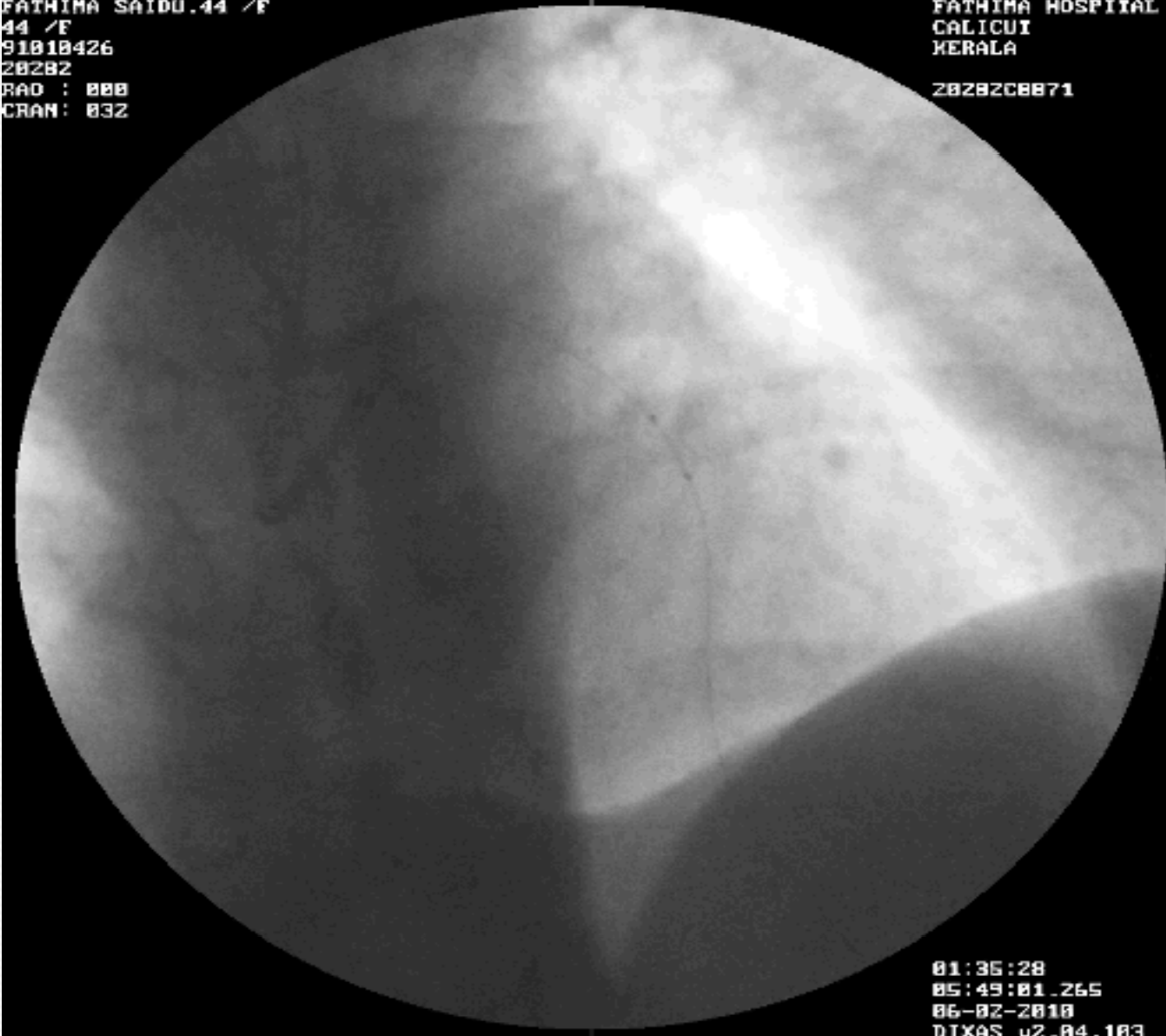
FATHIMA HOSPITAL
CALICUI
KERALA
20202C0070



01:35:28
05:45:42.281
06-02-2010
DIXAS v2.04.103

FATHIMA SAIDU.44 /F
44 /F
91010426
20202
RAD : 000
CRAN: 032

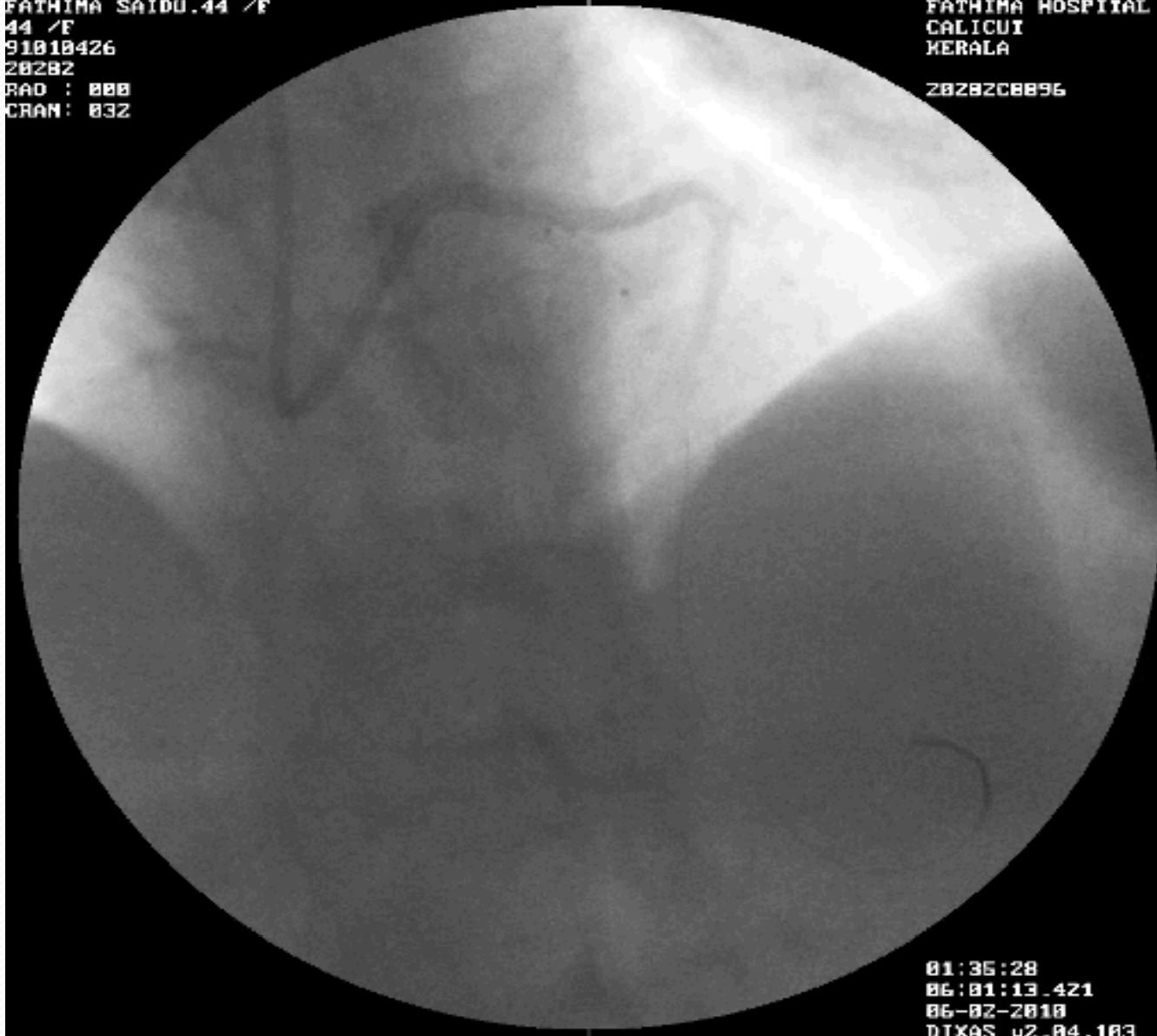
FATHIMA HOSPITAL
CALICUI
KERALA
2020200071



01:35:28
05:49:01.265
06-02-2010
DIXAS v2.04.103

FATHIMA SAIDU.44 /F
44 /F
91010426
20202
RAD : 000
CRAN: 032

FATHIMA HOSPITAL
CALICUI
KERALA
20202CBB96

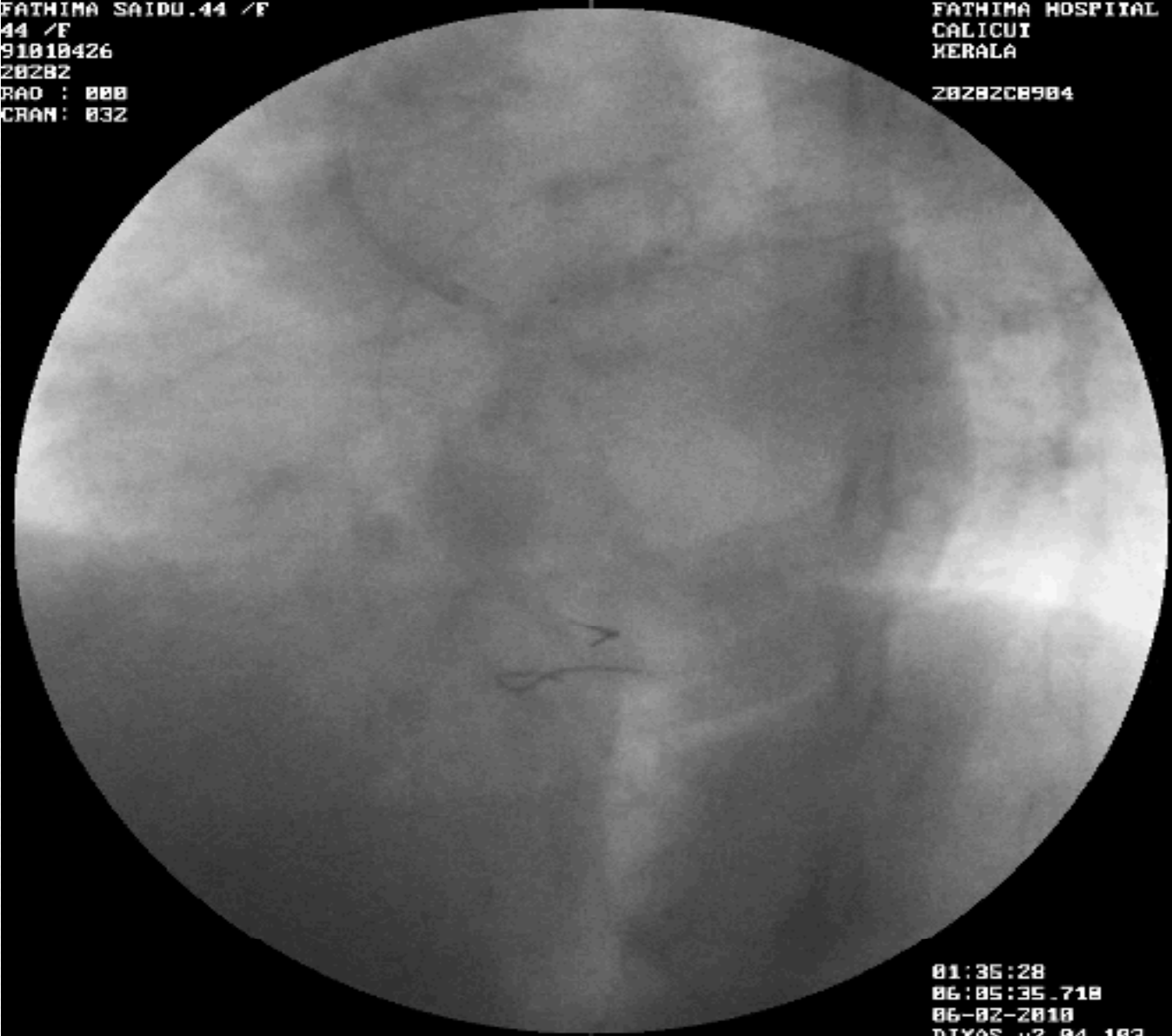


01:35:28
06:01:13.421
06-02-2010
DIXAS v2.04.103

FATHIMA SAIDU.44 /F
44 /F
91010426
20202
RAD : 000
CRAN : 032

FATHIMA HOSPITAL
CALICUT
KERALA

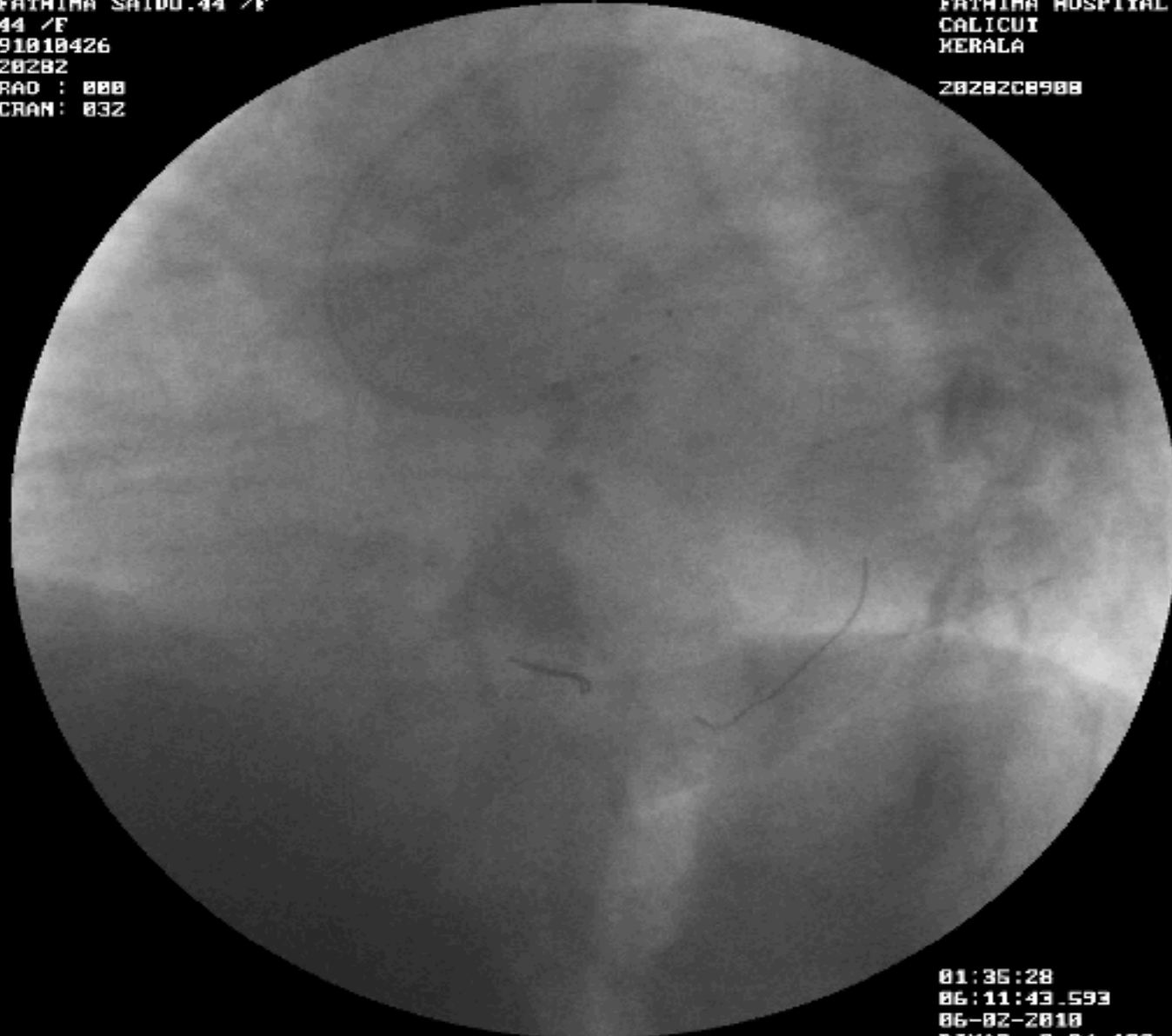
Z020200904



01:35:28
06:05:35.718
06-02-2010
DIXAS v2.04.103

FATHIMA SAIDU.44 /F
44 /F
91B1B426
20202
RAD : 000
CRAN: 032

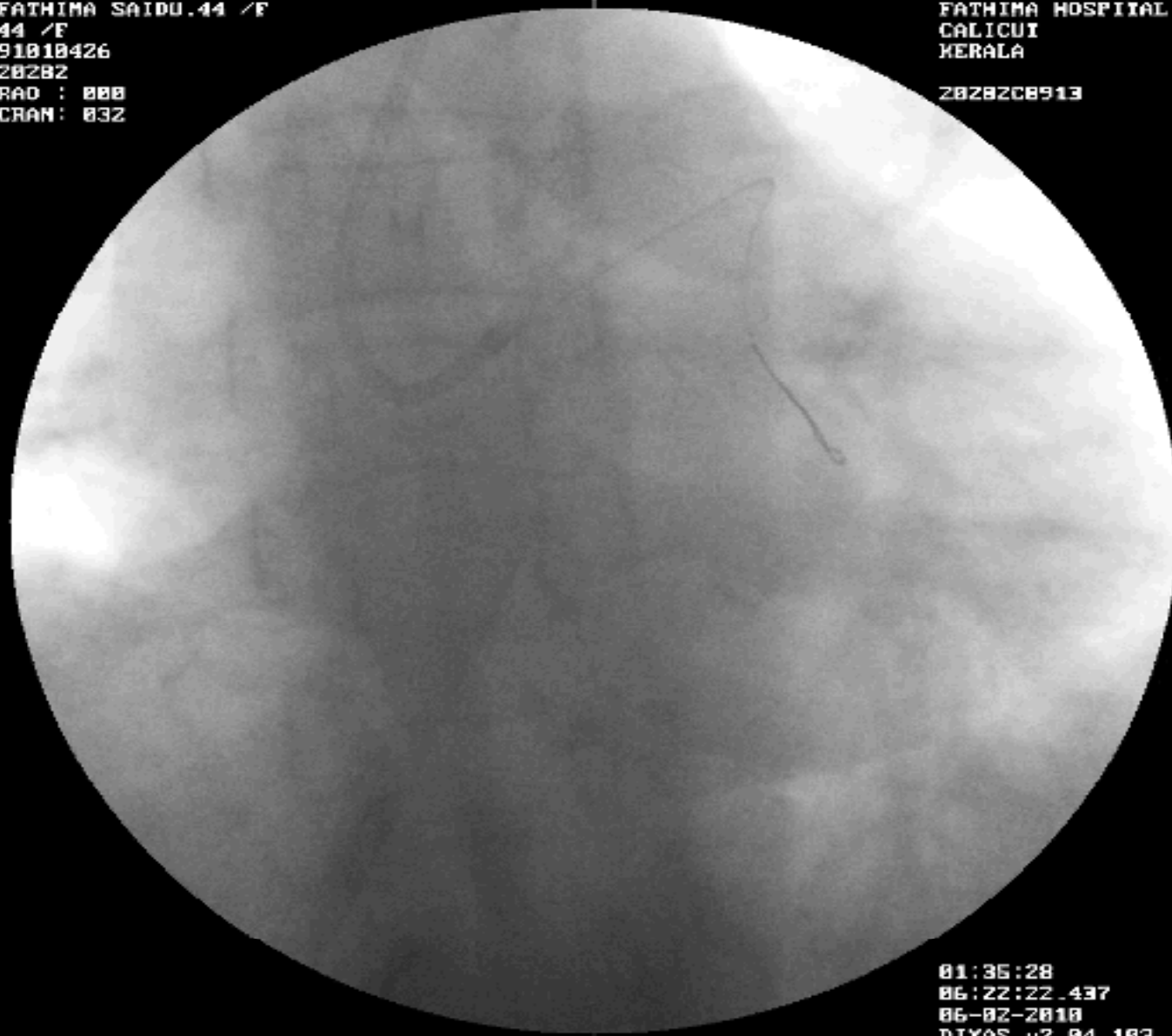
FATHIMA HOSPITAL
CALICUI
KERALA
202020900



01:35:28
06:11:43.593
06-02-2010
DIXAS v2.04.103

FATHIMA SAIDU.44 /F
44 /F
91010426
20202
RAD : 000
CRAN: 032

FATHIMA HOSPIAL
CALICUI
KERALA
202020913

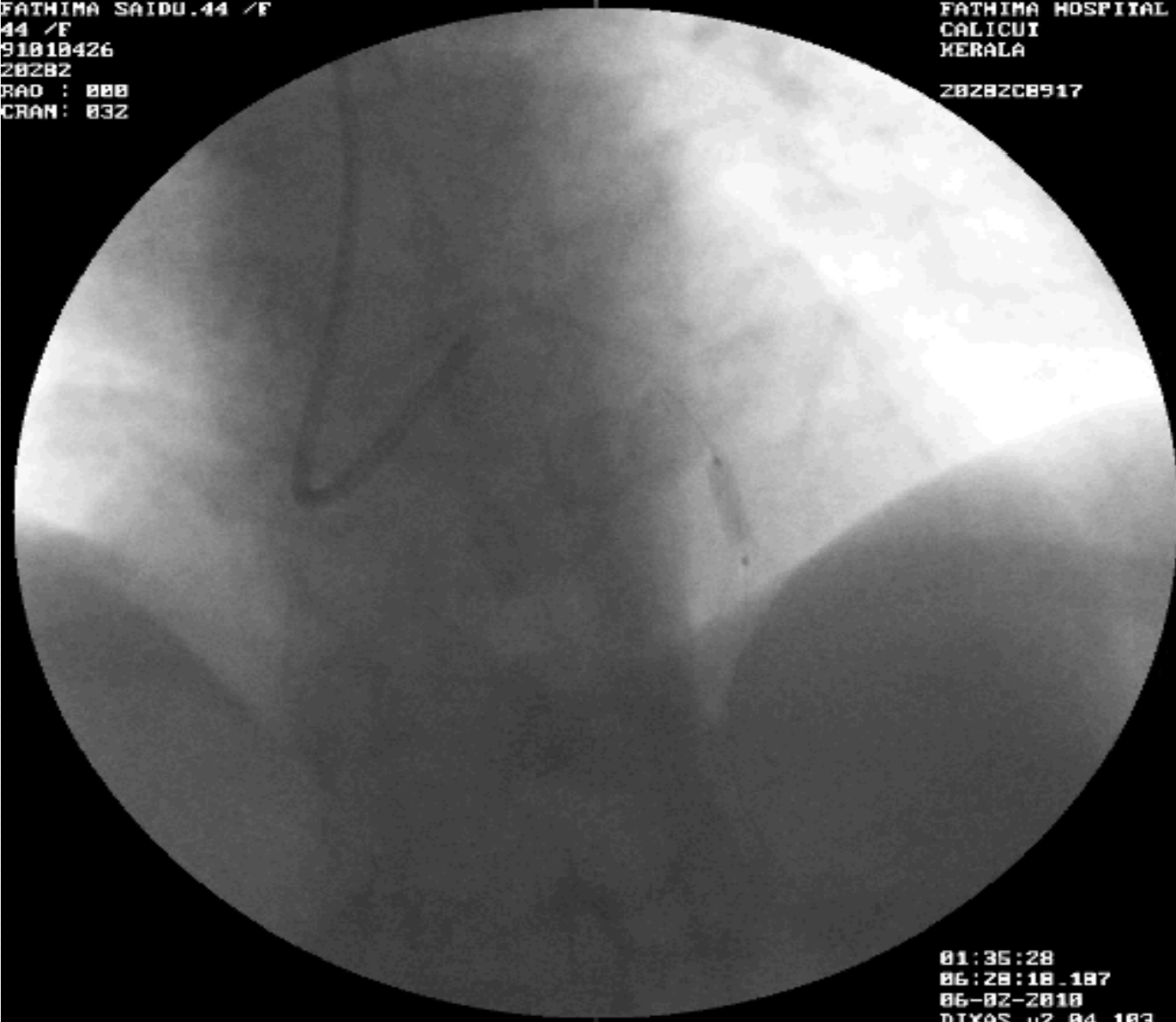


01:35:28
06:22:22.437
06-02-2010
DIXAS v2.04.103

FATHIMA SAIDU.44 /F
44 /F
91010426
20202
RAD : 000
CRAN: 032

FATHIMA HOSPITAL
CALICUT
KERALA

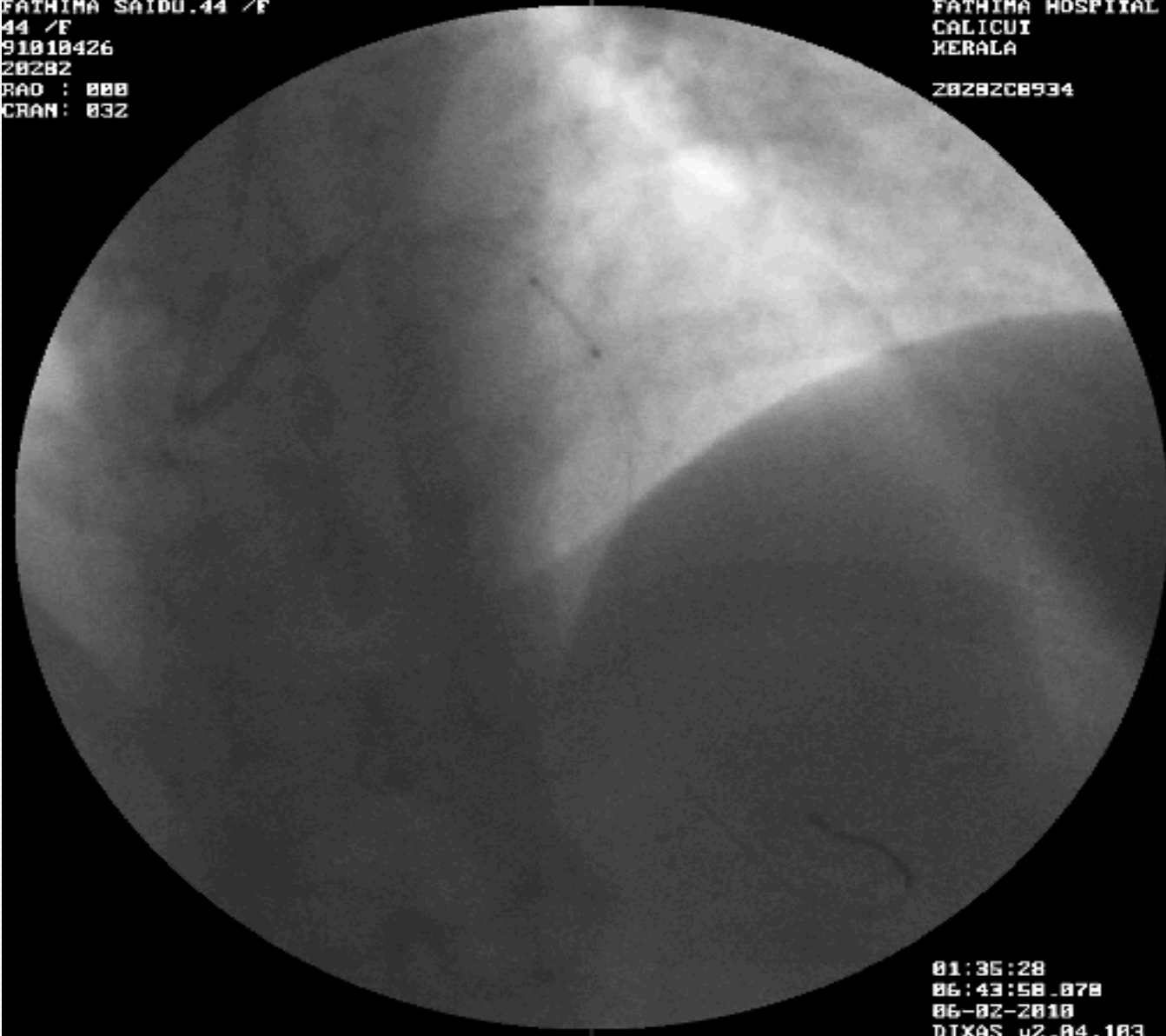
ZBZBZCB917



01:35:28
06:20:10_107
06-02-2010
DIXAS v2.04.103

FATHIMA SAIDU.44 /F
44 /F
91010426
20202
RAD : 000
CRAN: 032

FATHIMA HOSPITAL
CALICUI
KERALA
2020208934

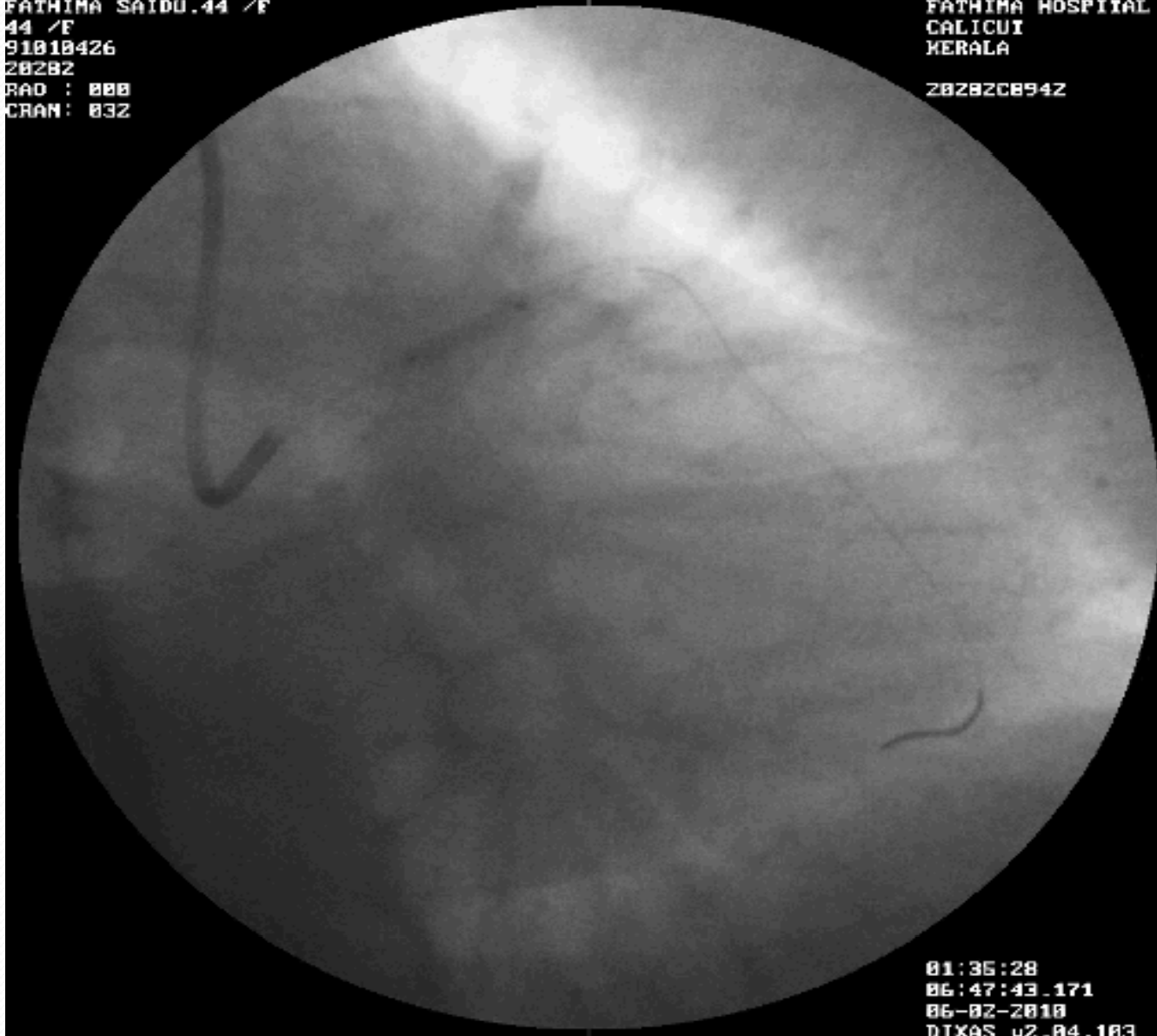


01:35:28
06:43:58.078
06-02-2010
DIXAS v2.04.103

FATHIMA SAIDU.44 /F
44 /F
91010426
20202
RAD : 000
CRAN: 032

FATHIMA HOSPITAL
CALICUI
KERALA

2020208942

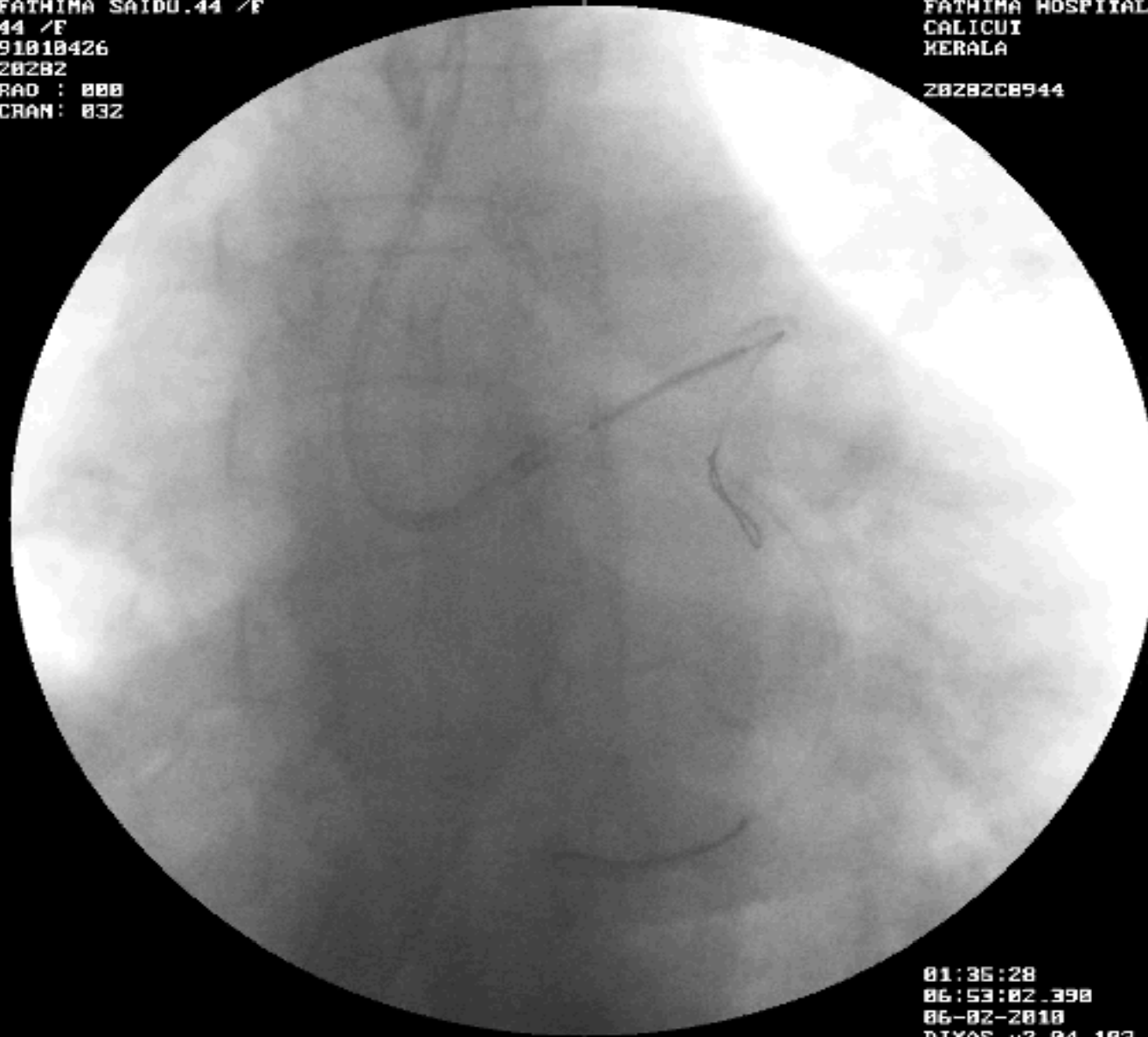


01:35:28
06:47:43.171
06-02-2010
DIXAS v2.04.103

FATHIMA SAIDU.44 /F
44 /F
91010426
20202
RAD : 000
CRAN: 032

FATHIMA HOSPITAL
CALICUI
KERALA

202020944

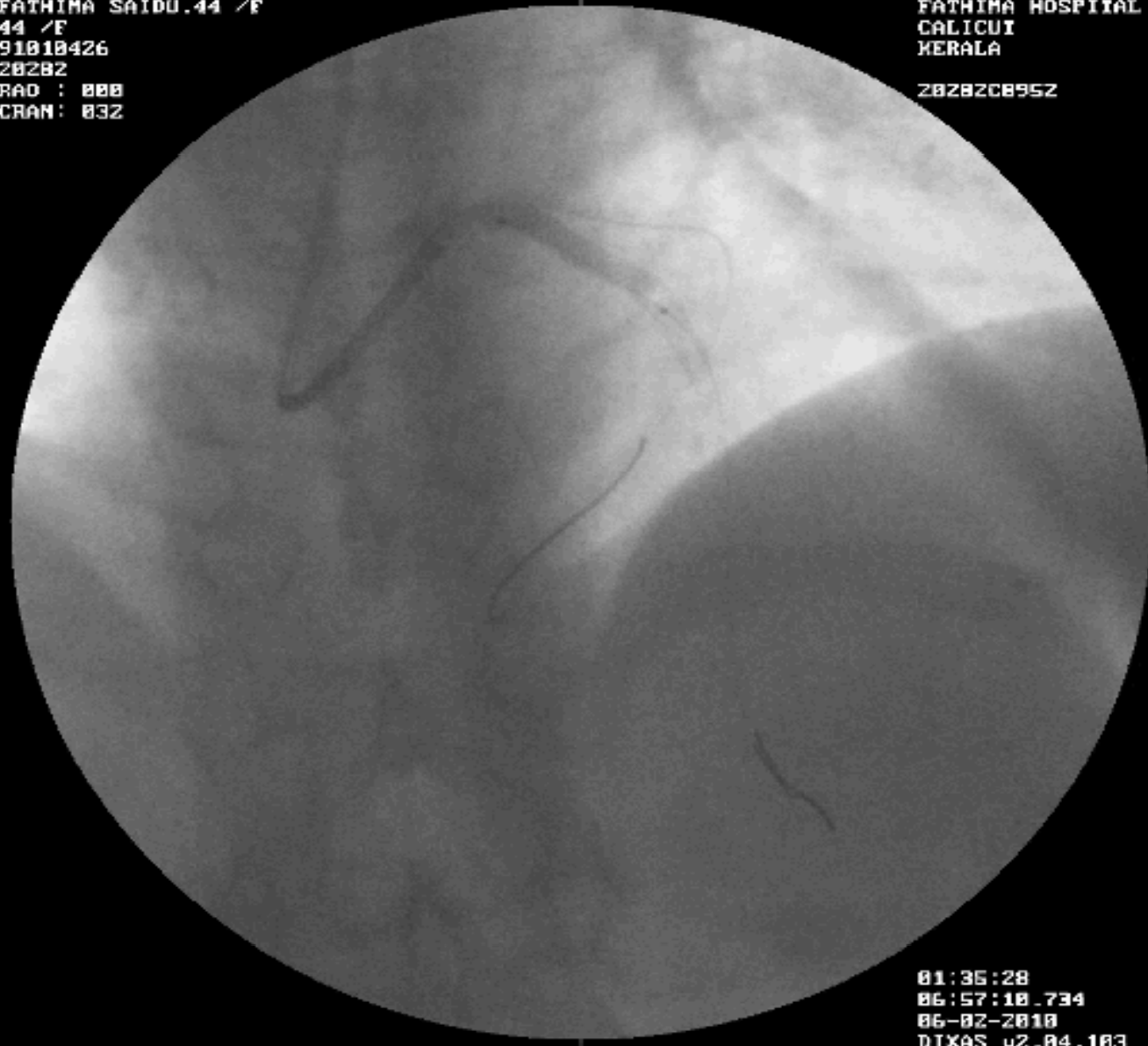


01:35:28
06:53:02.398
06-02-2010
DIXAS v2.04.103

FATHIMA SAIDU.44 /F
44 /F
91010426
20202
RAD : 000
CRAN: 032

FATHIMA HOSPITAL
CALICUI
KERALA

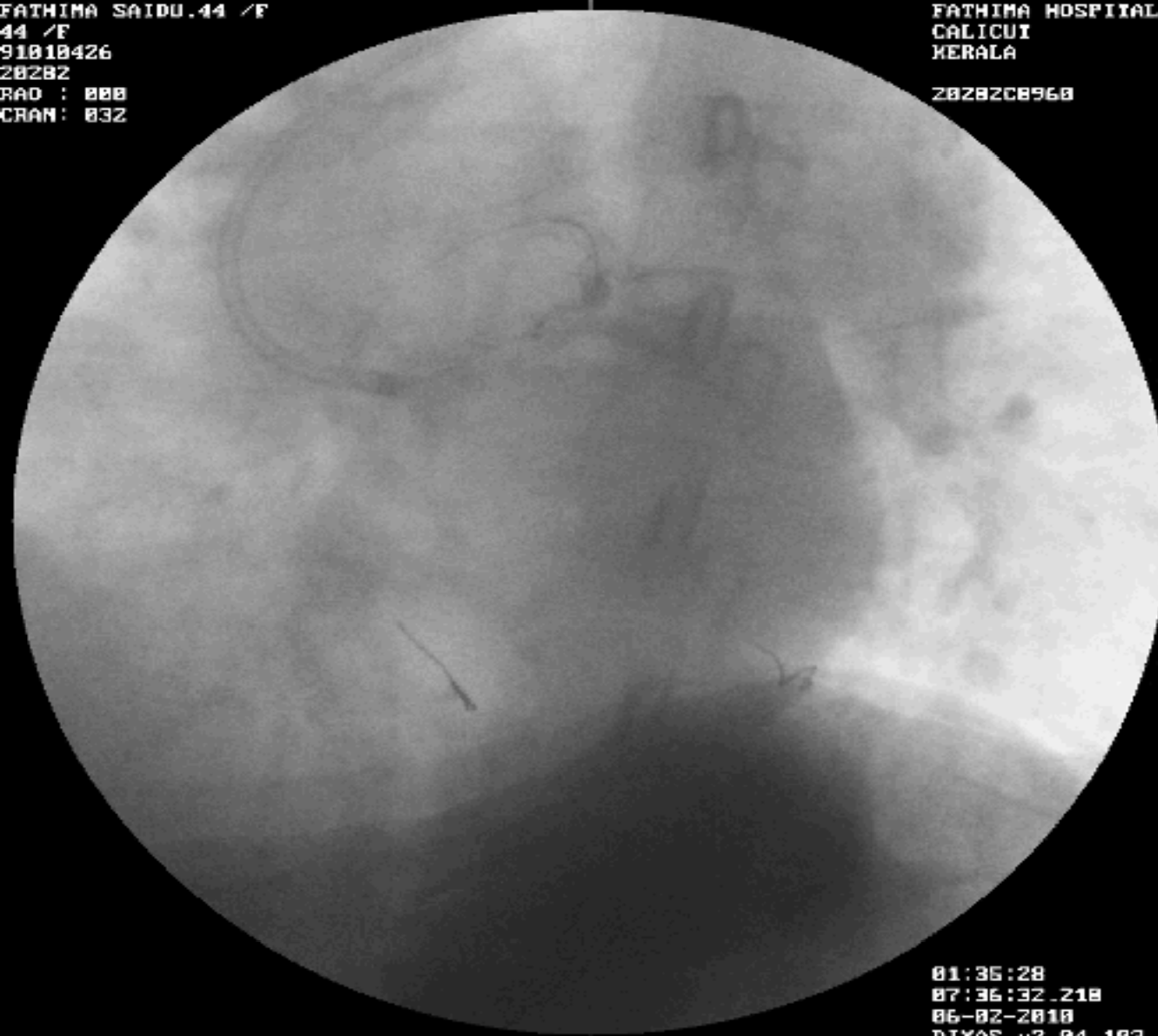
Z02020095Z



01:35:28
06:57:10.734
06-02-2010
DIXAS v2.04.103

FATHIMA SAIDU.44 /F
44 /F
91010426
20202
RAD : 000
CRAN: 032

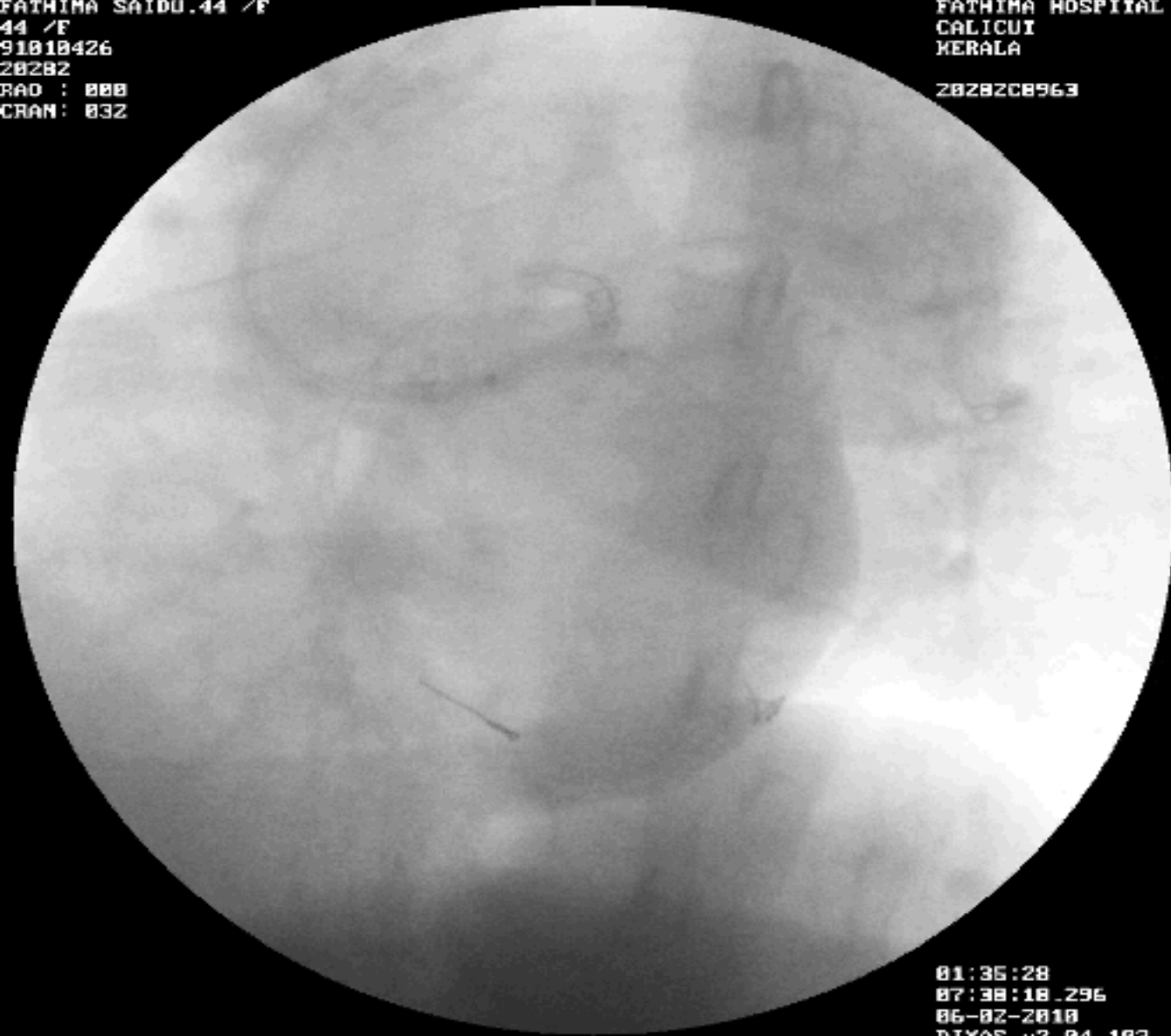FATHIMA HOSPITAL
CALICUI
KERALA
2020208960



01:35:28
07:36:32.218
06-02-2010
DIXAS v2.04.103

FATHIMA SAIDU.44 /F
44 /F
91010426
20202
RAD : 000
CRAN: 032

FATHIMA HOSPITAL
CALICUI
KERALA
2020208963

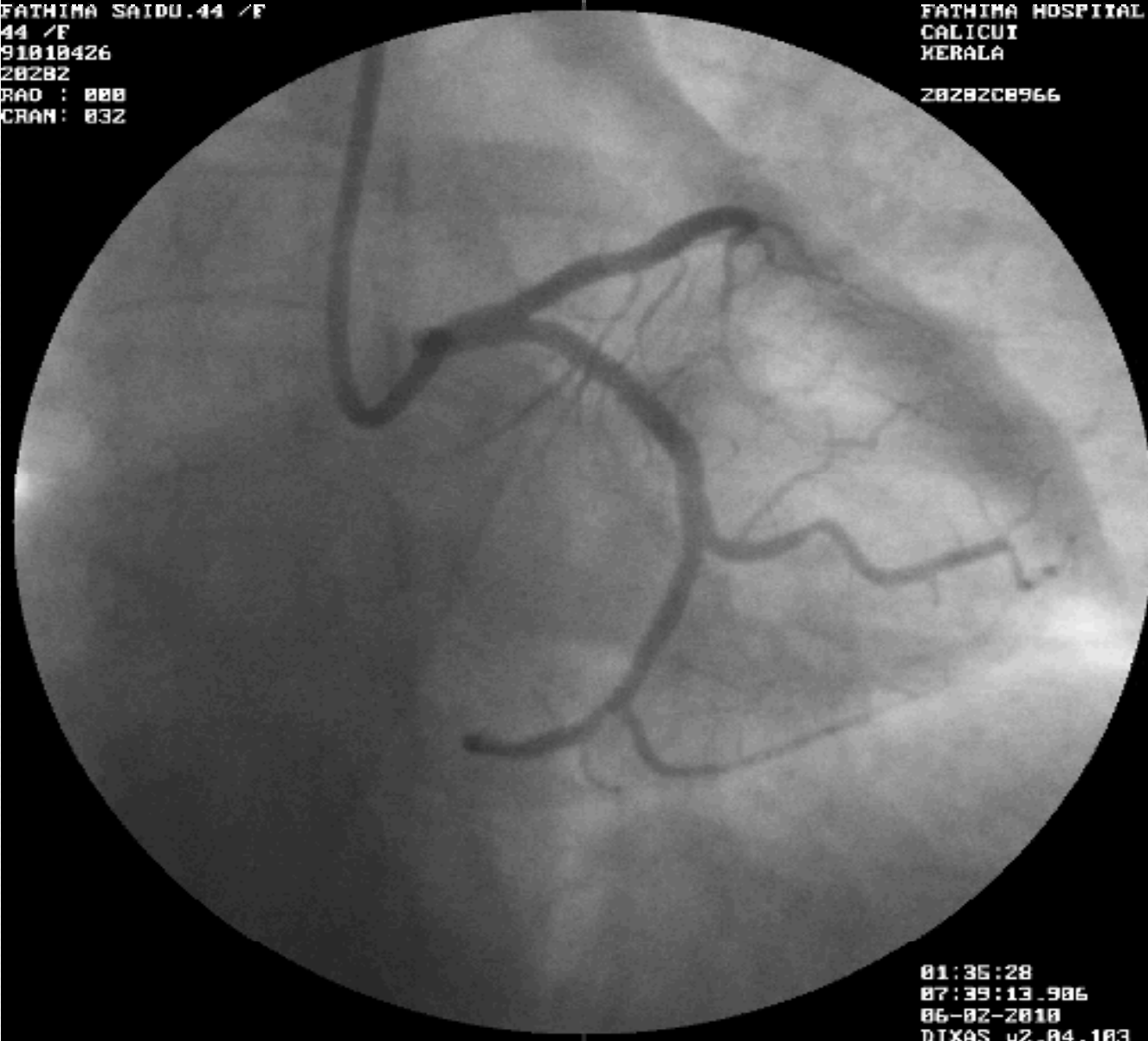


01:35:28
07:38:18.296
06-02-2010
DIXAS v2.04.103

FATHIMA SAIDU.44 /F
44 /F
91010426
20202
RAD : 000
CRAN: 032

FATHIMA HOSPITAL
CALICUI
KERALA

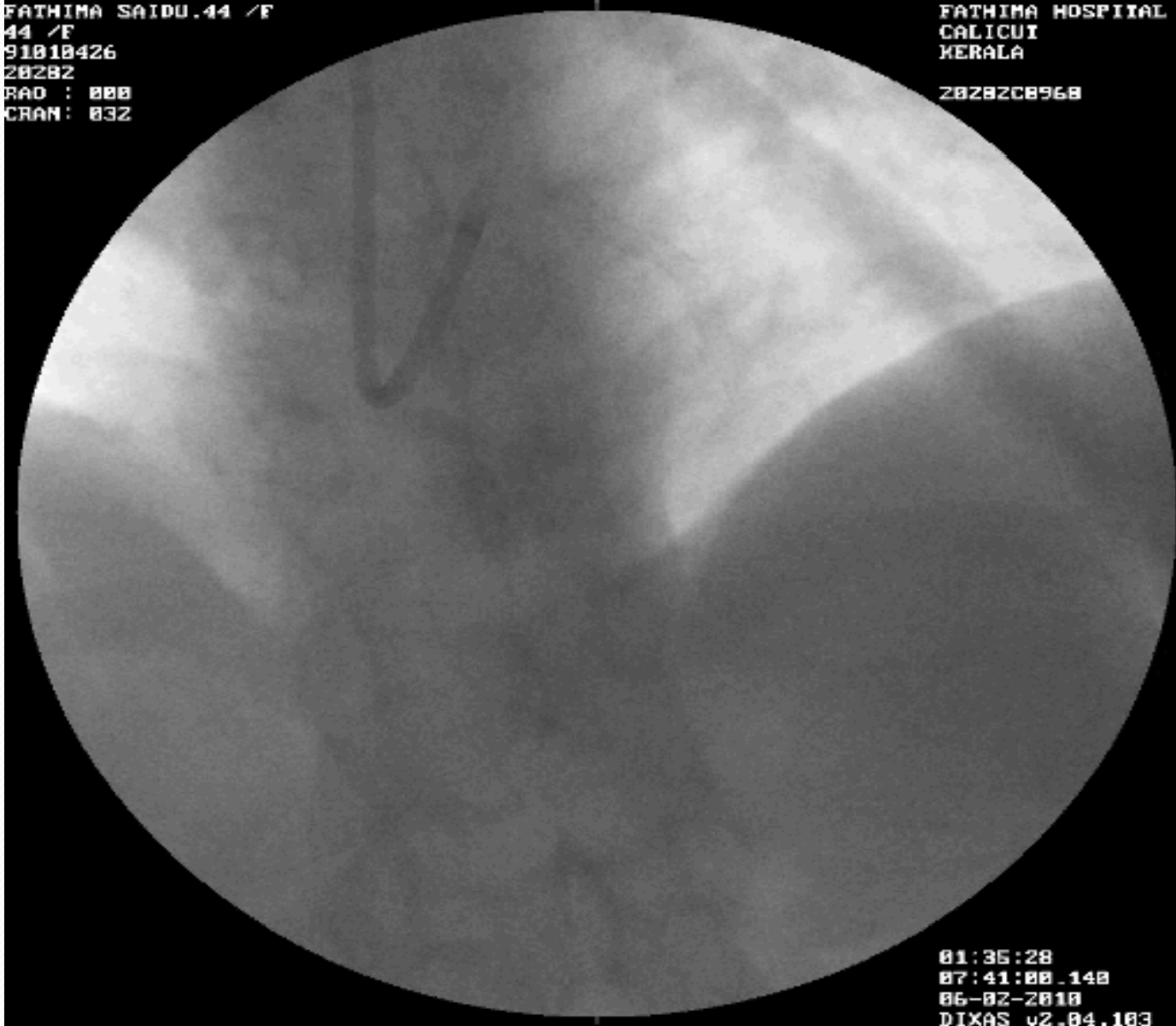
Z0Z0Z0B966



01:35:28
07:39:13.906
06-02-2010
DIXAS v2.04.103

FATHIMA SAIDU.44 /F
44 /F
91010426
20202
RAD : 000
CRAN: 032

FATHIMA HOSPITAL
CALICUT
KERALA
202020960

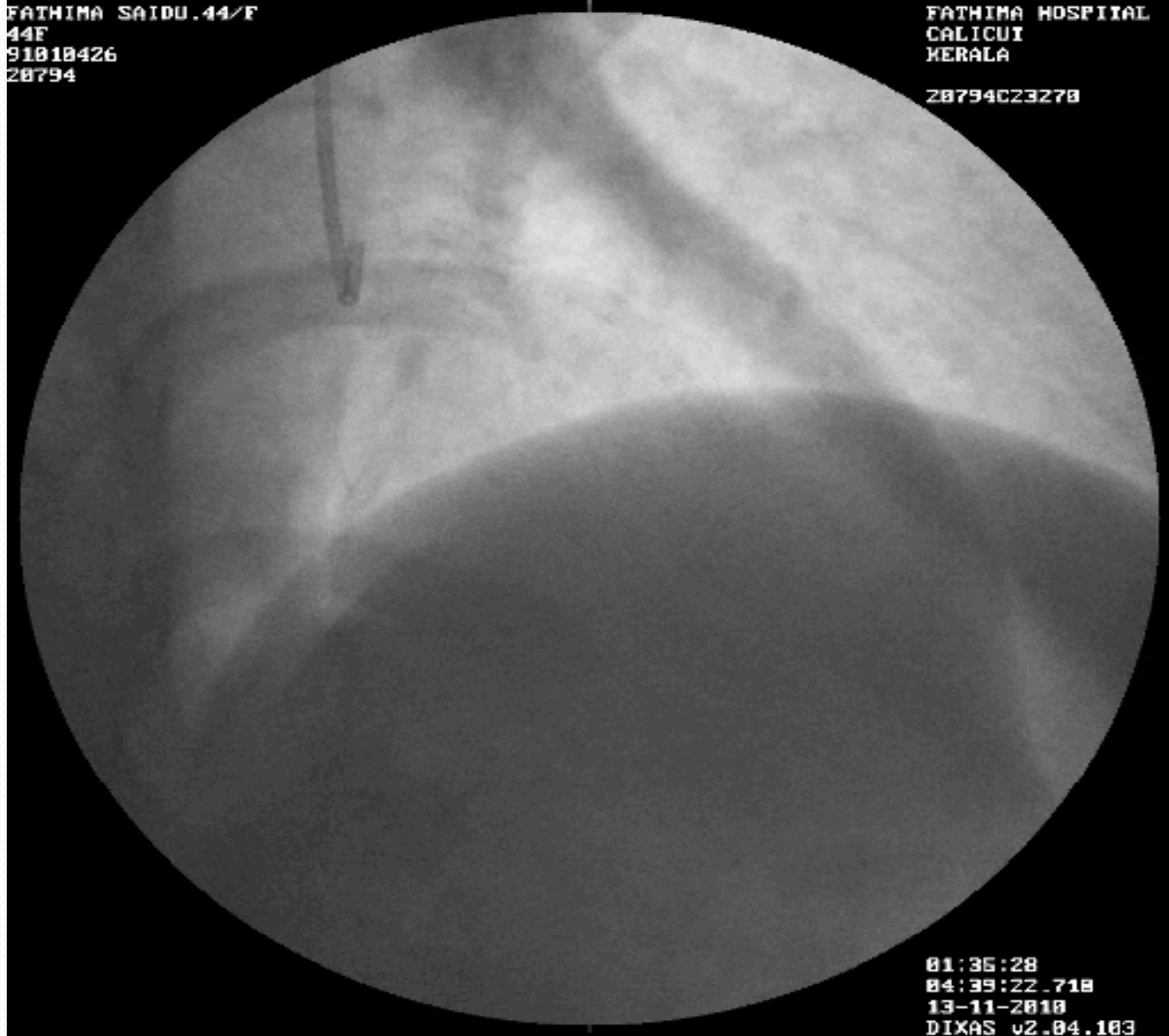


01:35:28
07:41:00_140
06-02-2010
DIXAS v2.04.103

FATHIMA SAIDU.44/F
44F
91010426
20794

FATHIMA HOSPITAL
CALICUT
KERALA

Z0794C23270

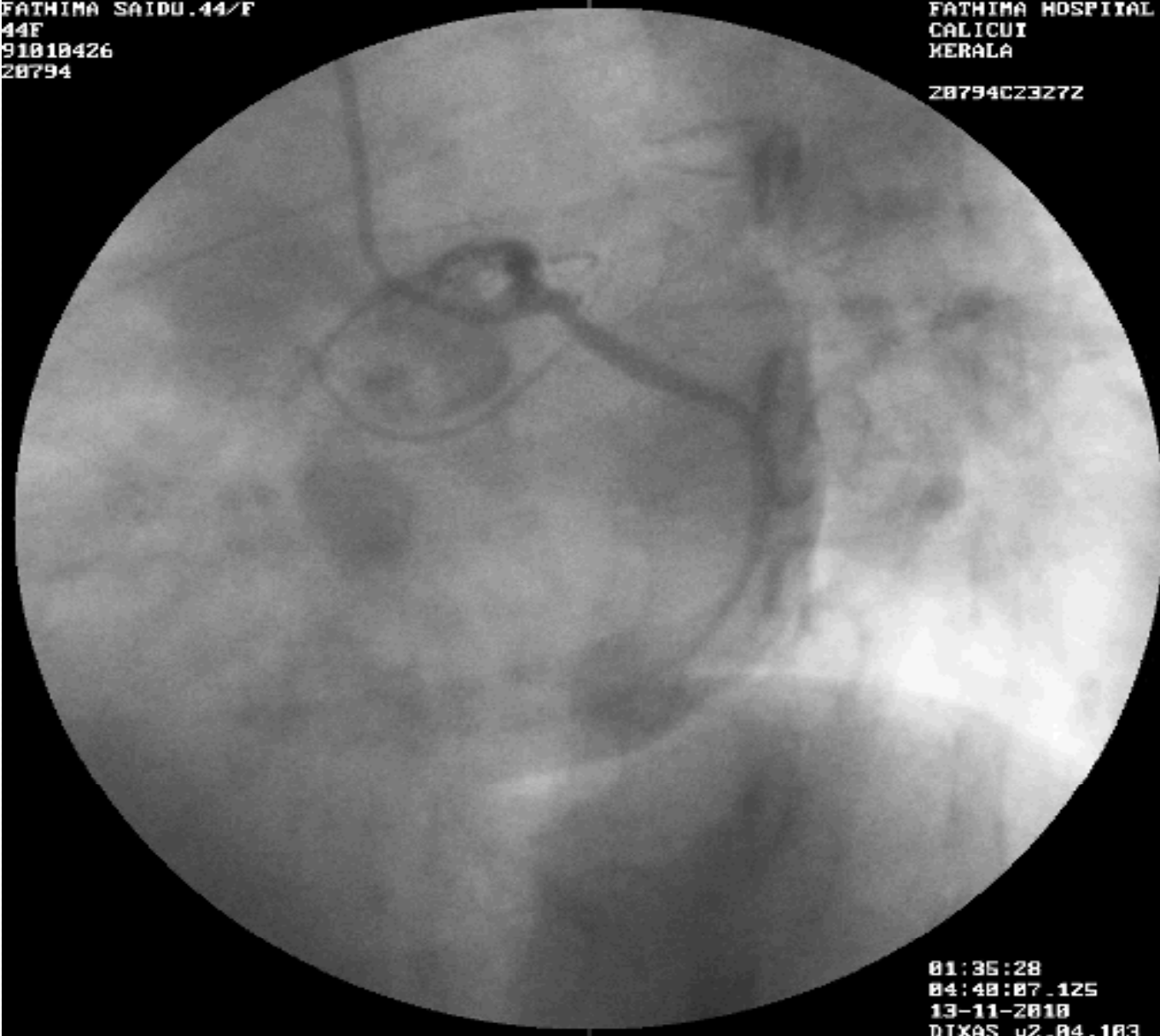


01:35:28
04:39:22.718
13-11-2010
DIXAS v2.04.103

FATHIMA SAIDU.44/F
44F
91010426
20794

FATHIMA HOSPITAL
CALICUT
KERALA

Z0794C2327Z



01:35:28
04:40:07.125
13-11-2010
DIXAS v2.04.103

CONCLUSION

- GUIDING INDUCED LEFT MAIN DISSECTION
- RETRO GRADE AORTIC SINUS DISSECTION
- ANTIGRADE OCLUSIVE DISSECTION OF LEFT DOMINANT LCX
- TRANS RADIAL CTO OF MID LAD
- OCCURRED BEFORE CORONARY WIRING
- MANAGED WITH LEFT MAIN STENTING FOLLOWED BY STENTING OF LCX, LPDA AND PTCA & STENTING OF CTO LAD
- GOOD IMMEDIATE AND LONG TERM RESULT